



King's Research Portal

DOI:

[10.1038/sj.bdj.2017.398](https://doi.org/10.1038/sj.bdj.2017.398)

Document Version

Peer reviewed version

[Link to publication record in King's Research Portal](#)

Citation for published version (APA):

Banerji, S., Mehta, S. B., & Millar, B. J. (2017). The management of cracked tooth syndrome in dental practice. *British Dental Journal*, 222(9), 659-666. <https://doi.org/10.1038/sj.bdj.2017.398>

Citing this paper

Please note that where the full-text provided on King's Research Portal is the Author Accepted Manuscript or Post-Print version this may differ from the final Published version. If citing, it is advised that you check and use the publisher's definitive version for pagination, volume/issue, and date of publication details. And where the final published version is provided on the Research Portal, if citing you are again advised to check the publisher's website for any subsequent corrections.

General rights

Copyright and moral rights for the publications made accessible in the Research Portal are retained by the authors and/or other copyright owners and it is a condition of accessing publications that users recognize and abide by the legal requirements associated with these rights.

- Users may download and print one copy of any publication from the Research Portal for the purpose of private study or research.
- You may not further distribute the material or use it for any profit-making activity or commercial gain
- You may freely distribute the URL identifying the publication in the Research Portal

Take down policy

If you believe that this document breaches copyright please contact librarypure@kcl.ac.uk providing details, and we will remove access to the work immediately and investigate your claim.

The management of Cracked Tooth Syndrome in Dental Practice

Dr Subir Banerji ² BDS MClinDent (Prosth) PhD MFGDP (UK)

Dr Shamir B. Mehta ¹ BDS BSc MClinDent(Prosth) MFGDP (UK)

Prof Brian J Millar³ BDS FDSRCS PhD FHEA

1- Senior Clinical Teacher, Deputy Programme Director MSc Aesthetic Dentistry; 2- Programme Director MSc Aesthetic Dentistry, Senior Clinical Teacher. 3- Professor, Consultant, Programme Director Fixed and Removable Prosthodontics

Corresponding Author

Dr Shamir B. Mehta

Address

Dept. of Conservative and MI Dentistry
Unit of Distance Learning,
Floor 18, Tower Wing, Guys Campus,
St Thomas's Street,
London.
United Kingdom
SE1 9RT

Please email all correspondence to : shamir.mehta@kcl.ac.uk

Abstract

Cracked Tooth Syndrome is a commonly encountered condition in dental practice, which frequently causes diagnostic and management challenges. This paper provides an overview of the diagnosis of this condition, and goes on to discuss current short and long-term management strategies applicable to Dental Practitioners.

Clinical Relevance

This paper covers the diagnosis and management of this common condition.

Objectives

To inform clinicians of the current thinking, as well as to provide an overview of the techniques commonly used in managing Cracked Tooth Syndrome.

Introduction

Cracks in teeth are exceedingly common. Some may become problematic and can lead to symptoms, cracked tooth syndrome and tooth loss.

A 'crack' may be defined as a 'line on the surface of something along which it has split without breaking apart', whilst a 'fracture' may be considered to be 'the cracking or breaking of a hard object or material' (www.oxforddictionaries.com).¹ Cracks on teeth may range from innocuous craze lines limited to the enamel layer, to a split tooth or one that may display the presence of a vertical root fracture. The term 'incomplete fracture', is used to describe a fracture plane of unknown depth and direction passing through tooth structure, that if not already involving, may progress to communicate with the pulp or periodontal ligament'.² Where the fracture plane may progress to the external surface of the tooth (either the clinical crown or root) or to the pulp chamber (culminating in apical periodontitis), a diagnosis of a *complete fracture* may apply. Complete and incomplete fractures may be subdivided into those that take a vertical or oblique direction.³

Incomplete fractures of posterior teeth are commonly (but not always) associated with the condition of cracked tooth syndrome, frequently abbreviated to CTS. Patients presenting with CTS often complain of symptoms of sharp pain on biting and thermal sensitivity, particularly during the consumption of cold foods and beverages.⁴ The intensity of the perceived pain on biting is often proportional to the magnitude of the applied force.⁵ Additional symptoms that are less frequently reported include, the perception of pain on release particularly when fibrous foods are eaten (a phenomenon termed 'rebound pain'), pain elicited by the act of tooth clenching or grinding

or by sugary substrates and less commonly by heat stimuli respectively. Sometimes, patients suffering from CTS are also able to accurately locate the affected tooth. The precise cause of the symptoms associated with CTS is unknown.^{6,7}

The aim of this article is to provide an overview of the condition of CTS, as well as to appraise traditional management strategies, including the description of a recently described technique to assist with the diagnosis, immediate management and subsequent treatment of CTS. It is however, important to appreciate that as such no singular 'concrete' method of treatment can be advocated by the authors at this point in time for the management of this problem. The latter is accountable for by a lack of depth and detail in the available evidence, with much of the current data being based on clinical audit(s) of a given approach, often where the sample sizes have been relatively small or follow-up being of a relatively short duration. There is also a need to take into account a variety of other factors, which may be addressed when attempting to gain valid informed consent, taking into additional account the skills and competence of an operator with a given protocol. Clearly, there is a need for further research into the efficacy of various techniques, ideally involving studies of the randomized controlled trial variety or longer term prospective trials.,

The Epidemiology and Aetiology of CTS

Cracked Tooth Syndrome appears to typically affect adult patients that are past their third decade, often affecting teeth that have previously received restorative intervention, although not exclusively.⁸ Possible reasons include older teeth having more restorations and may thus experience increased lateral occlusal load due to the possible loss of anterior guidance over time.

Mandibular molar teeth seem to be most commonly involved, followed by maxillary premolars, maxillary molars and mandibular premolars. In a recent clinical audit, mandibular first molar teeth were most commonly affected by CTS, possibly due to the wedging effect of the opposing prominent maxillary mesio-palatal cusp onto the mandibular molar central fissure.⁹

The aetiology of CTS is multifactorial. Causative factors include, previous *restorative procedures, occlusal factors, developmental conditions/ anatomical considerations, trauma* and *miscellaneous factors* (such as aging dentition with a concomitant reduction in physiological elasticity or the presence of lingual tongue studs).¹⁰

The Diagnosis of Cracked Tooth Syndrome (Figure 1)

The diagnosis of CTS is often based on the reporting of a history of cold sensitivity and sharp pain on biting hard or fibrous food, with an alleviation of symptoms on the release of pressure. However, the perceived symptoms may display variation in accordance to depth and orientation of the crack.¹¹ The

visual detection of a crack, often aided with the use of a sharp explorer probe ideally with magnification, may help to confirm a suspected diagnosis; however, not all cracks are symptomatic. The application of point load testing devices to apply a force to a suspected fracture is risky, due to the possibility of fracture of the tooth, restoration or the opposing tooth and therefore the authors do not recommend their use.

Hypersensitivity to an applied cold stimulant (indicative of pulpal inflammation) may also help to confirm a diagnosis of CTS. Affected teeth are however, seldom tender to percussion, by virtue of the absence of a complete fracture and the absence of irreversible pulpitis. The taking of radiographs to see a coronal crack can be of a limited diagnostic benefit, as cracks may run parallel to the plane of the film. The use of a light to trans illuminate a tooth can be helpful. It has been suggested that yellow/orange lights may be of greater value than blue light. However, blue lights are more readily available. Figure 1, includes a flow diagram, which may be used to assist with the diagnosis and management of CTS.

Consensus opinion would suggest that the presence of a history of symptoms as noted above, hypersensitivity to cold and a positive bite test are likely to indicate the presence of an incomplete tooth fracture. However, in the opinion of the authors it is common for a misdiagnosis to occur or indeed ambiguity to exist over a precise diagnosis, which may prove frustrating to all concerned, often necessitating specialist attention.¹²

The above is accounted for by there being several other conditions that may yield similar symptoms to those of CTS, including some commonly encountered conditions such as occlusal trauma, acute periodontal disease, dentine hypersensitivity, galvanic pain, post-operative hypersensitivity, fractured restorations, to less frequently diagnosed conditions such as trigeminal neuralgia and atypical facial pain.¹³ Establishment of an accurate diagnosis may also be compounded by the lack of sensitivity offered by the clinical tests described above and also by virtue of the presenting symptoms often displaying diversity and inconsistency (which may also relate to the exact depth and direction of the crack).⁹

The authors have recently described a useful clinically quick and easy way to establish or confirm a diagnosis with the use of a "trial" localized supportive composite splint.⁹ Here the suspected tooth exhibiting CTS symptoms of pain upon release is isolated using cotton wool rolls. Resin composite is placed onto the dried occlusal surface of the suspected tooth without any etching or bond application to a thickness of 1.0 to 1.5mm and wrapped across the external line angles of the tooth extending onto the (palatal/lingual and buccal) axial walls by 2-3mm. No effort is made to contour the material. Once the material has been cured, the un-bonded resin overlay has the potential to serve as an occlusal splint. The patient is warned that the tooth will feel proud and then asked to bring this tooth into contact with its antagonist and asked to bite and slowly increase the pressure as a repeat of the initial "bite" test. The absence of any pain upon release of the pressure may help to confirm a suspect diagnosis of CTS. An example of a trial splint, is shown by Figure 3.

The Management of CTS

A number of differing protocols have been described in the contemporary literature for the successful management of CTS.¹⁴ There is however, only limited data available documenting the relative merits and drawbacks of each. In the opinion of the authors, the selected protocol should offer an effective, efficient, economic, predictable and biologically conservative means of treating this condition.

Whilst some advocate the removal of the affected cusp, followed by restoration of the residual defect or subtractive occlusal adjustments¹⁵, the consensus approach for the management of incompletely fractured posterior teeth would generally appear to involve the *immobilization or splinting* of the affected tooth, so as to prevent the independent movement of the fractured portions upon occlusal loading. Immobilization in this manner may also prevent further progression of the fracture plane.^{16,17}

Where removal of the fractured cusp is to be undertaken, it should be performed with extreme caution, as there is a risk of attenuation of the fracture plane. Subtractive occlusal adjustment is invasive and will not help to avoid the continual flexure of the tooth upon loading when an occlusal load is applied.⁸ Cusp reduction to overlay it with a protective restorative material may be required: composite 2mm, gold and other alloys 1mm.

It is also important to check the anterior guidance when providing care. If necessary thought may be given to the 'building up' of any worn anterior teeth to increase the level of disclusion.

The Immediate Management of CTS

Traditionally, unless the affected cusp has been splintered off during the removal of an existing restoration when undertaking exploratory procedures, acute management has generally been provided using immediate extra-coronal circumferential splints (such as copper rings, orthodontic bands or provisional crowns)^{18,19} or by the application of direct (intra-coronal or extra-coronal splints) usually involving some form of tooth preparation, where some levels of biological compromise is likely to be incurred.^{20,21} Table 1 provides a summary of the traditional protocols used for the immediate management of CTS.

Table 1. A summary of some commonly used acute splints for the management of CTS in General Dental Practice; ^{18,19,20,21}

Method	Advantages	Disadvantages	Other comments
1. Copper rings & stainless steel orthodontics bands ^{12,18}	<ul style="list-style-type: none"> - Can be effective - Economical - Minimally invasive - Endodontic treatments may be performed whilst in situ - Can help to establish a definitive diagnosis 	<ul style="list-style-type: none"> -Not always at the disposal of a GDP - Skills & knowledge required to enable correct placement. - Placement may prove uncomfortable - Poor aesthetics - Food trapping with orthodontic bands 	<ul style="list-style-type: none"> - Must be well adapted circumferentially - Contoured appropriately - Must not interfere with the existing occlusal scheme - Should remain in situ for 2 to 4 weeks
2. Provisional crowns/overlays ¹⁹	<ul style="list-style-type: none"> - Can provide an effective means of immobilization - Most General Dental Practitioners will be confident and competent with clinical techniques 	<ul style="list-style-type: none"> - Time consuming to prepare; undue delays may result in fracture progression - Biologically invasive, with risks of pulp tissue trauma ^{20,21} 	

- **Direct intra-coronal restorations**

When using an intra-coronal restoration to treat an incompletely fractured posterior tooth, the objective is to anchor the chosen dental material to the

cavity walls at either side of the fracture plane, which would help to not only prevent the independent movement of the portions either side of the fracture plane, but also aid in restoring the intrinsic fracture toughness of a tooth.

The use of *adhesively retained silver amalgam restorations* has been described for the successful management of CTS.²² However, the evidence is very limited.

There is some evidence to support the short-term prescription of *direct, resin bonded posterior composite restorations* to treat cases of CTS.²³ Opdam et al evaluated the efficacy of direct composite intracoronal resin restorations (to treat painful, cracked posterior teeth where there were pre-existing silver amalgam restorations). Cases were followed up for a period of seven years; an annual failure rate of 6% was reported. This compared less favorably to where a second sample had received directly bonded resin overlay restorations. It was suggested that the inferior success of the intracoronal approach might relate to the progressive breakdown of the adhesive interface (between the tooth and restoration) with cyclical functional loading. The latter would thereby hamper the longer-term ability of the restoration to effectively splint the crack. This may be of particular concern amongst patients who may display a tendency towards parafunctional tooth clenching and grinding habits. Cuspal contraction that may also occur as a consequence of polymerization shrinkage when placing composite resin restorations may have the unwanted effect of causing further propagation of the fracture.

Two clinical studies have shown that the use of a flexible polymer resin such as in SDR Bulk Fill (Dentsply) can reduce contraction stresses as well as increase the risk of cuspal fracture, which may prove to be of future merit.^{24,25}

The longer term management of CTS

It has been suggested that the placement of a restoration that provides cuspal coverage has the potential to restore the fracture toughness of a restored tooth to that of an intact tooth.²⁶ In the case of a posterior tooth with a crack that has extended into dentine, it is reasonable to assume that the fracture toughness of the affected tooth is likely to be undermined. For this reason, it would seem prudent to restore such a tooth by the means of a restoration that provides cuspal protection and limiting cuspal flexure. This may be achieved by an onlay, overlay or crown restoration. Restorations that provide cuspal coverage may be fabricated directly or indirectly.

- **The use of direct onlay restorations to treat CTS**

The use of direct materials to provide longer-term management of CTS has a number of clear merits; Table 2 has summarized these.

Direct onlays used to treat incompletely fractured posterior teeth may be formed using *silver amalgam*²⁷ or *resin composite*.²³ With the availability of

adhesively retained materials, direct silver amalgam overlays are rarely provided in general dental practice.

Opdam et al, have reported very favorable longer-term success for the use of *direct resin onlays* for the management of incomplete posterior tooth fractures. The direct composite onlay restoration, therefore offers a lesser invasive and aesthetic alternative to use of dental amalgam overlays for this purpose.²³ It is likely, that a reduction in the height of the affected cusp will reduce the leverage placed on it when an occlusal load is applied, whilst the its coverage with a plastic material will not only provide a form of 'shock absorption' but also help to divert occlusal loads from the crack towards the axial walls (to which the overlay will be anchored) and ultimately down the long axis of the tooth (which may in turn also lessen the stresses applied to the adhesive interface) and optimize restoration longevity.

Table 2. Merits of direct onlay restorations for the management of CTS.

- Restorations may be placed in a single visit; this may prove time effective.
- Provisional restorations are avoided; provisional restorations are not as well adapted as definitive restorations, which may facilitate the continual ingress of noxious stimuli or microorganisms into the crack. Provisional restorations will nether provide the same level of cuspal support as a definitive restoration formed from a more robust dental material.
- Costly laboratory fees are averted.
- Should endodontic therapy be subsequently required, pulp chamber access through a direct restoration is less challenging than through an indirect restoration; the resulting access cavity may be readily repaired, without an absolute need to replace a costly indirect restoration.

Indirect Restorations with cuspal coverage

Indirect techniques offer the use of dental materials which have the potential to offer superior mechanical properties in the oral environment, and are perhaps lesser demanding of operator skill versus the use and placement of direct onlay restorations.¹⁴ When using occlusal coverage restorations, the cusp angle should be reduced to reduce the risk of lateral loading.

Channa et al²⁸ have reported the successful application of resin bonded alumina abraded Type III cast gold alloy onlays for the management of CTS over a mean service period of 4.0 years. However, a relatively small sample of cases was included. The latter restorations have the potential to offer superior marginal adaptation and finish, favorable wear characteristics and a high level of corrosion resistance.

The use of ceramic onlays to treat CTS should *perhaps* be undertaken with an element of suspicion. Ceramics are relatively brittle materials, that display limited ability of plastic deformation under load. The presence of a lower elastic modulus in comparison to resin composite based materials culminates in a superior ability (of the latter material) to absorb compressive loads by 57% versus that displayed by dental porcelains.²⁹ Thus, ceramics are less likely (in theory) to offer desirable 'shock absorbing' properties, with the possibility of an incomplete alleviation of symptoms as well as the risks of continued fracture propagation. Furthermore, intra-oral adjustments with dental ceramic materials may be challenging. There is however, very limited data to support (or indeed contraindicate) the use of ceramic onlays to treat CTS.¹⁴ Given the current lack of any substantive evidence to contraindicate the application of ceramic based materials for the management of CTS, it would perhaps be appropriate to not completely discount their application for the treatment of cracked teeth based simply on the findings of this laboratory study alone as the evidence is not conclusive. Further evidence is clearly required.

Indirect composite onlays may provide an aesthetic alternative to the use of ceramic, with the merits of ease of adjustment, and repair (which may be relevant if subsequent endodontic treatments are required). A retrospective study by Signore et al has reported very promising results for the use of bonded indirect resin onlays for the treatment of cracked, painful posterior teeth. A survival rate of 93% over a period of six years amongst a sample of 43 teeth was determined.⁵

Indirect adhesive onlay techniques offer a more conservative alternative to full coverage restorations. However, there still exists the need for subtractive tooth preparations if restorations are to conform to the existing occlusal scheme. The use of in-surgery CAD/CAM manufacturing techniques may however offer some potential, by overcoming difficulties such as the challenges associated with provisionalisation, which may increase the risks of pulpal complications amongst incompletely fractured teeth.¹⁶

The prescription of full coverage crowns has been suggested to be the most suitable form of treatment for the management of CTS.³² This is based on the potential ability of the resistance form provided by such restorations to help dissipate applied occlusal loads over the entire prepared tooth, as well as the retention form (by frictional contact) to provide effectual immobilization. Indeed, a bespoke preparation design has been advocated for cracked teeth including; an additional level of reduction of the affected cusp.³⁰

Full coverage crowns do not however offer a biologically conservative, time efficient and cost effective approach to the management of CTS. Indeed, endodontic complications have been documented as a significant concern when adopting this protocol, with approximately one-fifth of a sample of 127 teeth affected by CTS requiring subsequent root canal treatment within the first 6 months of placement.³¹ The risks of irreversible pulp trauma appear to be exacerbated amongst teeth displaying an involvement of one of both of the

marginal ridges; furthermore, the prognosis of cracked, root filled teeth has been reported to be poor, Tan et al.³²

Teeth with symptomatic, incomplete fractures are likely to display a form of reversible pulpitis. It is likely that the further trauma of subtractive preparations (to receive overlay restorations) coupled with the use of provisional restorations, pulp tissue trauma sustained during restoration try-in (which may also involved further tooth desiccation) and cementation will further increase the 'stresses' placed on the already inflamed and irritated tissues. This in turn, will further curtail the efficacy and predictability of indirect restorations to treat teeth affected by CTS (especially where more invasive preparation designs are applied).

- **A novel ultra-conservative approach to the management of CTS. (Figure 2)**

As an extension to the placement of a supra-coronal trial, directly non-bonded direct resin overlay (applied without any tooth preparation) to further help establish a diagnosis for CTS as described above, Banerji, Mehta, Millar et al have reported the successful placement of bonded, direct supra-coronal resin onlay restorations (DCS) for the treatment of incompletely fractured teeth by the means of a multi-centered retrospective audit, with an overall 86.7% success rate within 3 months of placement.⁹

The principles of this approach are based on those of well documented concepts of 'relative axial movement', which is commonly utilized to treat patients with pathological tooth, wear by minimal intervention.³³⁻³⁶

Supraocclusal restorations should be contoured to be flat so as to limit lateral loading. Given that definitive restorations have occlusal contour then the definitive restoration is not ideal for this use although they have been shown to be effective, Gerasimidou et al.³⁷ In each case, a careful assessment of placing a restoration in supra-occlusion was carried out, noting the eruptive potential of the patient, the risks of placing a supra-coronal restoration of the patient's oral health and informed consent was gained. Factors which may suggest the presence of a reduced eruptive potential include; the presence of an open bite, dental implants, fixed bridgework (with an abutment either side of the space), bony ankyloses, severe Class III malocclusions and the presence of prominent bony exostoses. Conditions which may also preclude the prescription of a supra-coronal restorations include; active periodontal disease, TMJ/PDS, prior orthodontic treatment, a heavily restored tooth (for instance a root filled tooth) or where the antagonistic tooth may be vulnerable to fracture.

However, intracoronal restorations should never be placed in supraocclusion, as they increase pulpal pain and may cause cusp fracture. Intentionally high restorations must have full occlusal coverage, free of endodontic pathology (including root canal fillings), no pathology present, with patient understanding and consent.

The clinical steps involved for this technique include (Figures 3 to 13) and a flow diagram is also provided (Figure 2):

- Confirming the complete elimination of the symptoms of rebound pain from the diagnosed tooth with a non-bonded composite splint as described above.
- An evaluation of the periapical status and bone support with an accurate long cone periapical radiograph.
- An explanation of the technique should be provided to the patient, outlining the nature of the treatment along with instructions for anticipating the change in their occlusal scheme.
- The application of a slurry of pumice the occlusal and axial walls of the diagnosed tooth, or the alternative use of air-abrasion techniques.
- Conditioning for adhesive bonding using a total etch technique, involving the use of 37% phosphoric applied over the occlusal and the axial walls for 20secs, followed by thoroughly washing the surfaces and the subsequent drying of the etched surfaces.
- Placement and curing of the chosen bonding resin as per the manufacturers instructions.
- Placement of a composite resin on the occlusal surface and 2-3mm down the axial walls (buccal, palatal/lingual). The depth of composite resin placed on the occlusal surface should be to 1.0-1.5mm in thickness, along the axial walls composite to finish in an infinity bevel and supragingivally. Light cure to manufacturers instructions.
- The occlusal surface should to remain 'flat' with the absence of any contact during any excursive mandibular movements. In certain instances a canine rise may be added in composite to achieve this.
- Composite to be polished.
- The patient should be reviewed within in 1 week to confirm alleviation of symptoms, followed by a periodic review every 2 weeks until all other tooth contacts are re-established.
- Substitution the composite splint with a definitive adhesive restoration once other tooth contacts reestablished. Remove canine rise restoration if required.

Whilst further work is needed to fully support this approach, the use of a DCS restoration has the potential (where careful case selection is applied) to provide a conservative, effective, predictable, efficient and economical approach to the short to medium term management of CTS. It may be particularly appropriate where there may exist a doubt over the exact diagnosis. An extrapolation of this approach, may involve the placement of indirect adhesive onlays in supra-occlusion as a means for the long-term management of incompletely fractured teeth in an ultra-conservative manner, where there is little doubt over the diagnosis.

With the advancement of CAD-CAM technology the fabrication of the proposed onlay can now be produced at the chair side once the diagnosis has been established.

Conclusion

The diagnosis and management of CTS in dental practice can sometimes prove to be highly taxing on the operator. There is a need for an effective technique to provide immobilization. The DCS restoration may have considerable merits for the diagnosis and management of CTS in a predictable and minimally invasive manner. However, there is a need for further research into this technique, as well as into alternative forms of management as discussed above, in order to support (or indeed contraindicate) the notion of any one approach (inclusive of a given dental material and or restoration form) being superior to another.

References

1. Crack – definition of crack in English form the Oxford dictionary www.oxforddictionaries.com > dictionary.
2. Ellis SG. Incomplete tooth fracture-proposal for a new definition. Br Dent J 2001; 190: 424-428.
3. Silvestri A, Singh I. Treatment rationale of fractured posterior teeth. J Am Dent Assoc 1978; 97 : 806-810.
4. Cameron CE. The cracked tooth syndrome: additional findings. Jour Am Dent Assoc 1976; 93: 971-975.
5. Signore A, Benedicenti S, Covani U, Ravera G. A 4 to 6 year retrospective clinical study of cracked teeth restored with bonded indirect resin composite onlays. Int Jour Prosthodont 2007; 20: 609-616.
6. Davis R, Overton J. Efficacy of bonded and non-bonded amalgams in the treatment of teeth with incomplete fractures. Jour Am Dent Assoc 2000; 131: 496-478.
7. Dewberry JA. Vertical fractures of posterior teeth, Lieve FS(ed) Endodontic Therapy, 5th edition. St Louis: Mosby, 1996: 71-81.
8. Hiatt WH. Incomplete crown-root fractures in pulpal periodontal disease. J Periodontol 1973; 44: 369-379.
9. Banerji S, Mehta SB, Kamran T, Kalakonda M, Millar BJ. A multi-centered clinical audit to describe the efficacy of direct supra-coronal splinting – A minimally invasive approach to the management of cracked tooth syndrome. Journal of Dentistry 2014;**42**:862-871.
10. Lynch C, McConnel R. The cracked tooth syndrome. Jour Can Dent Assoc 2002; 68: 470-475.
11. Geurtsen W, Schwarze T, Gunay H. Diagnosis, therapy and prevention of the cracked tooth syndrome. Quintessence Int 2003; 34: 409-417.
12. Banerji S, Mehta SB, Millar BJ. Cracked tooth syndrome. Part 1 : aetiology and diagnosis. Br Dent J 2010; 208 : 459-463.
13. Turp C, Gobetti J. The cracked tooth syndrome: an elusive diagnosis. Jour Am Dent Assoc 1996; 127: 1502-1507.
14. Banerji S, Mehta SB, Millar BJ. Cracked tooth syndrome. Part 2 : restorative options for the management of cracked tooth syndrome. Br Dent J 2010; 208 : 503-514.
15. Agar JR, Weller RN. Occlusal adjustments for initial treatment and prevention of cracked tooth syndrome. Jour Prosthet Dent 1988; 60: 145-147.
16. Griffin J. Efficient, conservative treatment of symptomatic cracked teeth. Compendium 2006; 27: 93-102.
17. Liebenberg WH. Partial coverage indirect tooth coloured restorations; steps to clinical success. Am Jour Dent 1999; 12: 201-209.

18. Ehrmann EH, Tyas MJ. Cracked tooth syndrome: diagnosis, treatment and correlation between symptoms and post-extraction findings. *Australian Dent Jour* 1990; 35: 105-112.
19. Guthrie GC, Difiore PM. Treating the cracked tooth with a full crown. *Jour Am Dent Assoc* 1991; 122: 71-73.
20. Saunders WP, Saunders EM. Prevalence of periradicular periodontitis associated with crowned teeth in an adult Scottish subpopulation. *Br Dent J* 1988; 185: 137-140.
21. Cheung GS, Lia SC, Ng RP. Fate of vital pulps beneath a metal ceramic crown or a bridge retainer. *Int Endod Jour* 2005; 38: 521-530.
22. Bearn D, Saunders E, Saunders W. The bonded amalgam restoration – a review of the literature and report of its use in the treatment of four cases of cracked tooth syndrome. *Quintessence Int* 1994; 25: 321-326.
23. Opdam NJ, Roeters JJ, Loomans RA, Bronkhorst E. Seven year clinical evaluation of painful, cracked teeth restored with a direct composite restoration. *J.Endod* 2008; 34: 808-811.
24. Van Dijken JW. Randomised 2-year follow-up of posterior bulk-filled resin composite restorations. Presented at the 46th Meeting of the Continental European Division of the International Association for Dental Research with the Scandinavian Division (NOF). Florence. 2013. Available from: <http://www.dentsply.co.uk/products/restorative/composites/SDR> (accessed September 2014).
25. McGuirk C, Hussain F, Millar BJ (2016). Survival of direct posterior composites with and without a bulk fill base, *Int Dent J* in press
26. Hodd JAA. Biomechanics of the intact, prepared and restored tooth; some clinical implications. *Int Dent Jour* 1991; 41: 25-32.
27. Davis R, Overton J. Efficacy of bonded and non-bonded amalgams in the treatment of teeth with incomplete fractures. *Jour Am Dent Assoc* 2000; 131: 496-478.
28. Chana H, Kelleher M, Briggs P, Hopper R. Clinical evaluation of resin bonded gold alloys. *Jour Prosthet Dent* 2000; 83: 294-300.
29. Brunton PA, Cattell P, Burke FJT, Wilson NHF. Fracture resistance of teeth restored with onlays of three contemporary tooth-coloured resin-bonded restorative materials. *Jour Prosthet Dent* 1999; 82: 167-171.
30. Casciari BJ. Altered preparation design for cracked teeth. *Jour Am Dent Assoc* 1991; 130: 571-572.
31. Krell K, Rivera E. A six year evaluation of cracked teeth diagnosed with reversible pulpitis ; treatment and prognosis. *J Endod* 2007; 33: 1405-1407.
32. Tan I, Chen NN, Poon CY, Wong HB. Survival of root filled cracked teeth in a tertiary institution. *Int Endod Jour* 2006; 39: 886-889.
33. Dahl B, Krungstad O, Karlsen K, An alternative treatment of cases with advanced localised attrition. *J Oral Rehab.* 1975;2: 209-214.

34. Dahl B, Krungstad O. Long term observations of an increased occlusal face height obtained by a combined orthodontic/ prosthetic approach. *J Oral Rehab.* 1985; **12**: 173-170.
35. Poyser N, Porter R, Briggs P, Chana H, Kelleher M. The Dahl concept: past, present and future. *Br Dent J*; 2005; 198: 669-676.
36. Hemmings K, Darbar U, Vaughn S. Tooth wear treated with direct composite at an increased vertical dimension: results at 30 months. *J Prosth Dent.* 2000; **83**:287-293.
37. Gerasimidou O, Watson T, Millar BJ (2016). Effect of placing intentionally high restorations: randomized clinical trial. *Journal of Dentistry* 2016 in press.

Figures

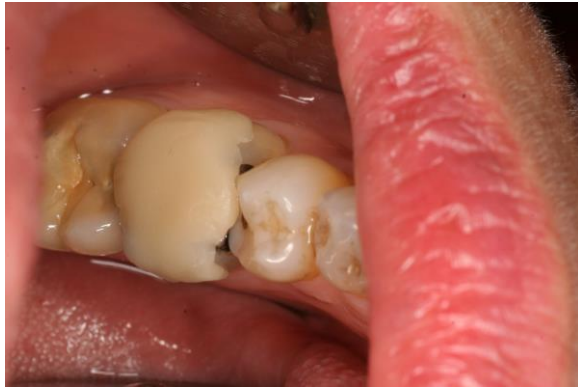

Figure 3. An example of a trial localised supportive composite splint

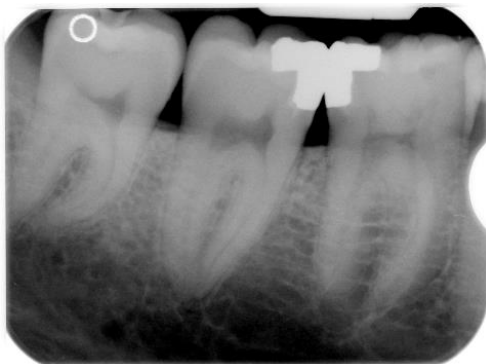


Figure 4. The lower right second molar has been diagnosed with CTS symptoms with 'rebound pain upon biting on a cotton wool roll.

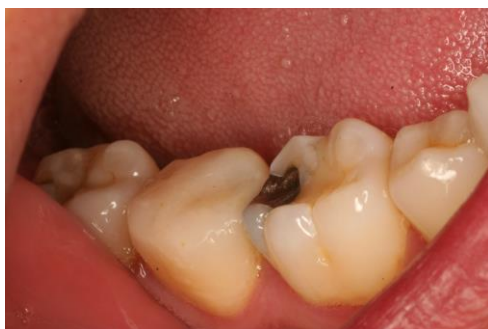

Figure 5. Following confirmation of the alleviation of symptoms with a "trial" splint (as shown in Figure 1) a bonded Direct Composite Splint (DCS) is placed on the lower right second molar tooth.

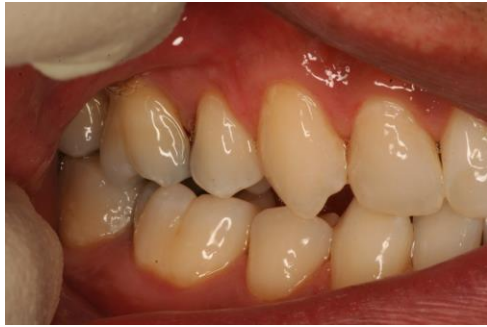

Figure 6. The separation of the teeth is shown here following placement of the DCS.

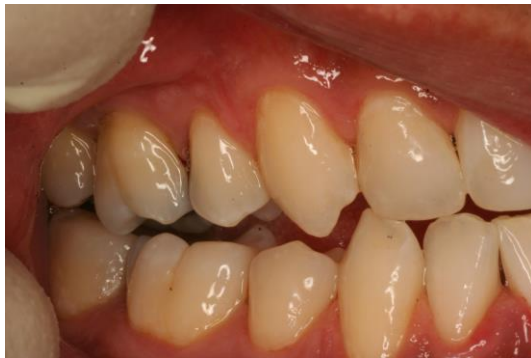

Figure 7. Shows upon right lateral excursion the posterior teeth along with the tooth with the DCS is out of contact with lower right canine guidance.

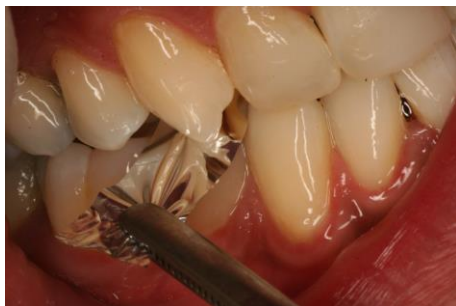

Figure 8. The teeth have now re-established contact in the intercuspal position and the symptoms are resolved from the lower right second molar tooth.

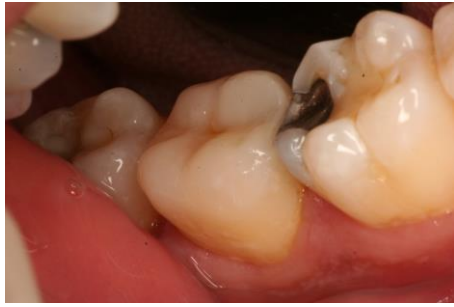

Figure 9. The DCS has been replaced with a Direct composite onlay following resolution of symptoms and reestablishment of the occlusion.

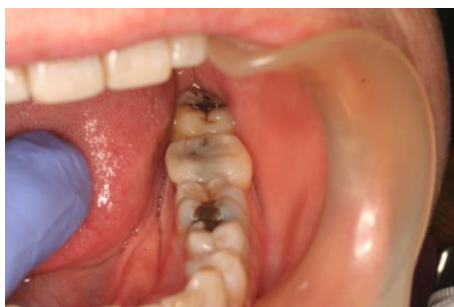

Figure 10 Shows another case where the diagnosed lower left second tooth has had placement of the DCS.

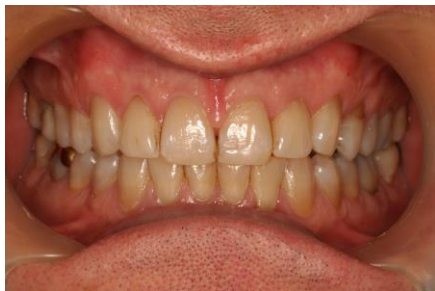

Figure 11. Shows teeth are held separated by the DCS for the case shown in figure 10, however there is no posterior teeth contacting on any excursive movements of the mandible.

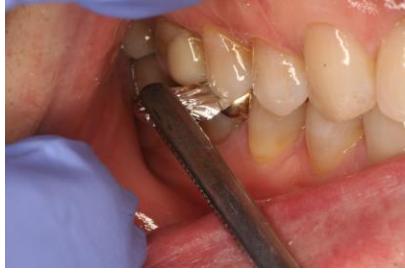

Figure 12. The occlusion has been re-established after a period of 3 months following DCS placement for case shown in figure 10.

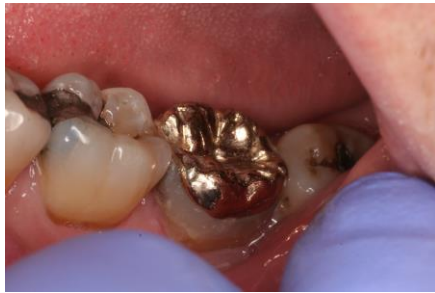

Figure 13. The DCS has been replaced with a Type III cast adhesive gold onlay for the case shown in figure 10.

Figure 2: A novel ultra-conservative approach to the management of CTS.

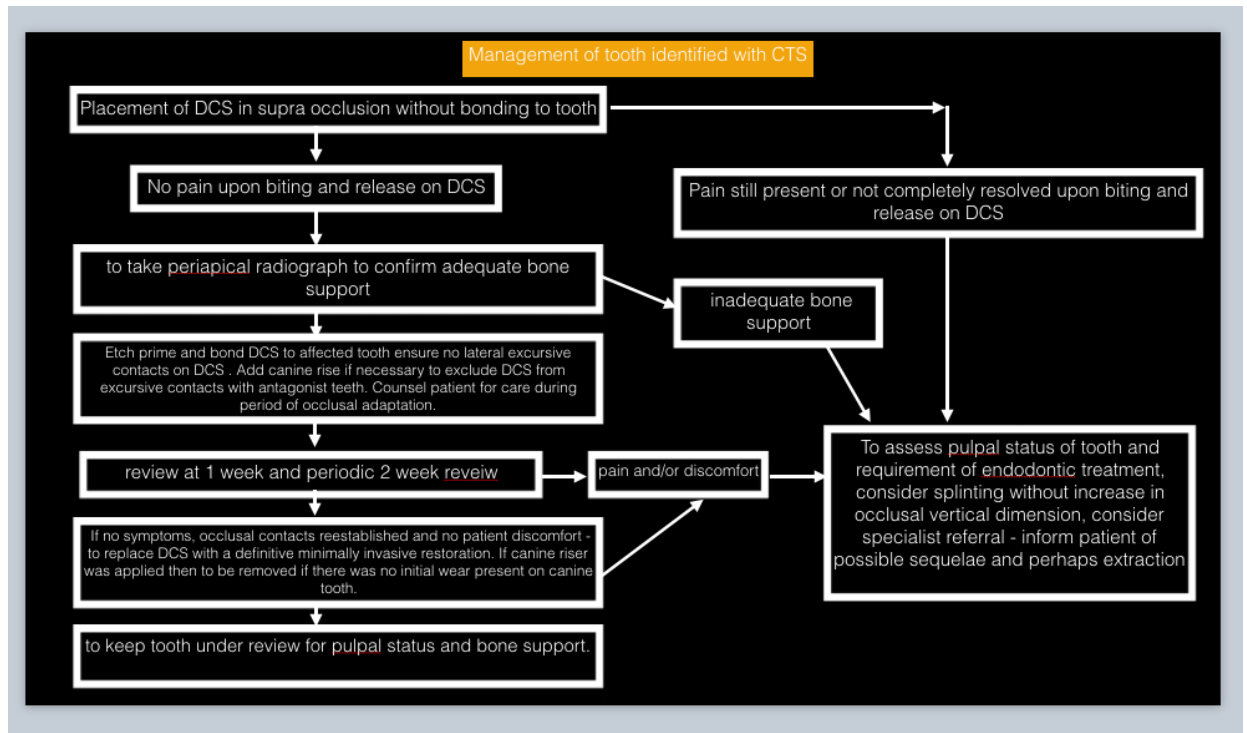


Figure 1 CTS flow chart – A guide to diagnosis and management

