DOI:
10.1016/j.jtcvs.2016.07.078

Accepted Manuscript

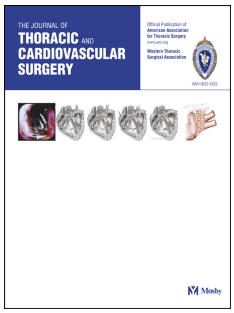

Thoracic Endovascular Aortic Repair (TEVAR) in Proximal (Type A) Aortic Dissection: Ready for a Broader Application?

Christoph A. Nienaber, MD, PhD, Natzi Sakalihasan, MD, PhD, Rachel E. Clough, MD, PhD, Mohamed Aboukoura, MD, Enrico Mancuso, MD, James S.M. Yeh, MD, PhD, Jean-Olivier Defraigne, Nick Cheshire, MD, PhD, Ulrich Peter Rosendahl, MD, Cesare Quarto, MD, John Pepper, MD, PhD

PII: S0022-5223(16)31049-2

DOI: 10.1016/j.jtcvs.2016.07.078

Reference: YMTC 10824

To appear in: *The Journal of Thoracic and Cardiovascular Surgery*

Received Date: 17 May 2016

Revised Date: 6 July 2016

Accepted Date: 30 July 2016

Please cite this article as: Nienaber CA, Sakalihasan N, Clough RE, Aboukoura M, Mancuso E, Yeh JSM, Defraigne J-O, Cheshire N, Rosendahl UP, Quarto C, Pepper J, Thoracic Endovascular Aortic Repair (TEVAR) in Proximal (Type A) Aortic Dissection: Ready for a Broader Application?, *The Journal of Thoracic and Cardiovascular Surgery* (2016), doi: 10.1016/j.jtcvs.2016.07.078.

Thoracic Endovascular Aortic Repair (TEVAR) in Proximal (Type A) Aortic Dissection: Ready for a Broader Application?

Christoph A. Nienaber[1,5] MD, PhD, Natzi Sakalihasan[2] MD, PhD, Rachel E. Clough[3,6] MD, PhD, Mohamed Aboukoura[4] MD, Enrico Mancuso[1] MD, James S. M. Yeh[1,5] MD, PhD, Jean-Olivier Defraigne[2], Nick Cheshire[1] MD, PhD, Ulrich Peter Rosendahl[1] MD, Cesare Quarto[1] MD, John Pepper[1] MD, PhD

[1] Royal Brompton Hospital, London, UK
[2] Université Catholique de Liège, Belgium
[3] Aortic Centre, Hôpital Cardiologique, CHRU Lille, France
[4] University of Rostock, Department of Cardiology, Germany
[5] National Heart and Lung Institute, Imperial College London, UK
[6] Division of Imaging Sciences and Biomedical Engineering, King's College London

Corresponding Author:
Christoph A. Nienaber, MD, FESC, FACC
Cardiology and Aortic Centre
Royal Brompton Hospital
Royal Brompton and Harefield NHS Foundation Trust
Syndey Street
London SW3 6NP
UK
Phone: +44 (0)20 7352 8121 ext 2838
Fax: +44 (0)20 7351 8634
E-mail: c.nienaber@rbht.nhs.uk

Word count 3032
Conflicts of interest No potential conflicts exist for all authors.
Funding No funding was provided for this work.

Abbreviations

aTAAD	acute type A aortic dissection
CT	computed tomography
cTAAD	subacute or chronic type A aortic dissection
D	diameter
EKG	electrocardiogram
EuroSCORE II	European System for Cardiac Operative Risk Evaluation II
F	female
IRAD	International Registry of Acute Aortic Dissections
L	length
LCCA	left common carotid artery
M	male
N	number
NA	not applicable
NBS	non-bare stent
PA	pseudoaneurysm
RCA	right carotid artery
RFV	right femoral vein
SD	standard deviation
SG	stent-graft
TA	transapical
TAVR	transcatheter aortic valve replacement
TAx	transaxillary
TEVAR	thoracic endovascular aortic repair
TF	transfemoral

ABSTRACT

OBJECTIVE: Thoracic endovascular aortic repair (TEVAR) has demonstrated encouraging results and is gaining increasing acceptance as a treatment option for aortic aneurysms and dissections. Yet, its role in managing proximal aortic pathologies is unknown - this is important because in proximal (Stanford type A) aortic dissections, 10-30% are not accepted for surgery, and 30-50% are technically amenable for TEVAR. We describe our case series of type A aortic dissections treated using TEVAR.

METHODS: Between year 2009 and 2016, 12 patients with acute, subacute or chronic type A aortic dissection with the proximal entry tear located between the coronaries and brachiocephalic artery were treated with TEVAR at 3 centers. Various stent-graft configurations were used to seal the proximal entry tear in the ascending aorta under rapid pacing.

RESULTS: 12 patients (9 male, 3 female), mean age 81±7 years, EuroSCORE II 9.1±4.5, underwent TEVAR for the treatment of type A aortic dissection. Procedural success was achieved in 11/12 patients (91.7%). There was one intra-procedural death and one minor stroke. No additional deaths at 30 days. At 36 months, there were 4 further deaths (all from non-aortic causes). The mean survival of these 4 deceased was 23 months (range 15-36 months). Follow-up computed tomography demonstrated favorable aortic remodeling.

CONCLUSION: TEVAR is feasible and reveals promising early results in selected patients with type A aortic dissection who are poor candidates for surgical repair. The current iteration of stent-graft technology however needs to be adapted to the specific features of the ascending aorta.

Abstract word count: 248

Central Message

TEVAR in type A aortic dissection is feasible in selected patients. Favorable aortic remodelling occurs in type A (and B) dissections. Thus TEVAR may be an option in patients at high risk for surgery.

Perspective Statement

TEVAR offers a potential treatment option in a subset of patients with type A aortic dissection at high surgical risk but with suitable anatomy. With TEVAR, 30 day survival is >90% in these high surgical risk patients. With this proof of concept study, broader application may be possible with further specific technological advances.

Central Picture legend

Successful interventional treatment of a type A aortic dissection using TEVAR

INTRODUCTION

The surgical mortality and morbidity remains high for proximal (Stanford type A) aortic dissections, particularly in the elderly with significant co-morbidities, despite recent strides to improve its surgical technique and management (1, 2). Considering the Western demographics with increasing aging population and variety of co-morbidities which portend inherent increased surgical risks, the concept of endovascular stent-grafting also known as thoracic endovascular aortic repair (TEVAR) (a catheter-based non-surgical technique) in patients with thoracic aortic disease is increasingly attractive, propelled by the desire to minimize surgical risks. TEVAR has been shown to initiate healing and remodelling of the dissected aorta, by excluding and depressurizing the false lumen (3-5). To date, TEVAR strategies appear encouraging in the treatment of various aortic pathologies (6-10). The technology has been embraced without level I evidence for the treatment of distal (Stanford type B) aortic dissections, and even used to treat acute proximal (Stanford type A) aortic dissections (11). However, the complexity of the anatomy in the ascending aorta continues to be a major obstacle for the use of endovascular technologies.

Acute type A aortic dissection usually requires very urgent surgical repair of the ascending aorta (12-14); selected cases however may qualify for TEVAR as an option in scenarios of unacceptably high surgical risk. According to the International Registry of Acute Aortic Dissections (IRAD), 86% patients qualify for surgical replacement of the ascending aorta, 23% or 12% require additional partial or total arch replacement, respectively (15). Overall, on aggregate 91% of patients in this registry underwent surgical repair under cardiopulmonary bypass with 25% in-hospital mortality (15, 16). A less traumatic repair of type A aortic dissection using TEVAR, where applicable, may potentially lower the procedural/in-hospital mortality risk, particularly as the technology improves.

Surgical repair leaves a patent false lumen in both the aortic arch and descending aorta in 75% patients, those who survive often require distal re-interventions (15, 16). One solution may be a two-stage hybrid procedure, whereby initially, surgery is performed to replace the ascending aorta together with aorto-brachiocephalic artery bypass without hypothermic circulatory

arrest. This is followed on a second occasion by surgery for left carotid artery bypass and TEVAR to retrogradely place an endovascular stent-graft in the thoracic aorta transfemorally in the same setting. The stent-graft excludes the retrogradely perfused distal false lumen (17). The objective of such an approach is to avoid surgery on the arch, and to complete the repair with an aortic stent-graft in a minimally invasive way. Such approach not only minimizes the procedural risks, but also enables careful evaluation of the distal false lumen prior to stent-graft placement. Alternatively, one-stage hybrid procedures combining open (surgical) insertion of an tube-graft in the ascending aorta with head vessel transposition and antegradely placing an endovascular stent-graft in the arch and descending aorta are feasible (18), but require the skills of both a cardiac and endovascular specialist and lack the precision of the two-stage hybrid procedure (19). Moreover, there is some resistance to apply such one-stage hybrid procedures in acute type A aortic dissections, because experts are aware that the fragile outer aortic wall and friable dissecting lamella are prone to injury or perforation by antegrade positioning of the stent-graft under conditions of circulatory arrest. At present there are no dedicated stent-grafts for the ascending aorta, in particular for the repair of aortic dissections; such challenges will certainly be addressed by customized stent-graft technology in the near future. Nevertheless, the concept of a one-stage hybrid repair with antegrade stent-graft placement may become part of a therapeutic armamentarium for complex type A dissections with distal malperfusion; while a multi-stage hybrid repair incorporating retrograde stent-graft placement may become a preferred option in stable situations.

From an anatomical perspective, 30–50% patients with type A aortic dissection are amenable to TEVAR (20, 21). Thus in the future more patients may be considered suitable for TEVAR with life-long follow-up. The ultimate goal is a fully catheter-based approach to repair the ascending aorta that minimizes procedural risk and initiates healing (as documented in type B dissections where interventional entry closure is associated with thrombosis of the false lumen and favorable aortic remodelling) (3, 4, 6, 7). Such approach is feasible with current technology (22-25). Here, we describe our 12-case series of type A aortic dissections treated using TEVAR.

172

173 **METHODS**

174

175 *Patient selection*

176 Between year 2009 and 2016, 12 patients with type A aortic dissection
177 consisting of an isolated dissection entry in the ascending aorta, referred to the
178 University Heart Centre (Rostock, Germany), CHU (Liege, Belgium) and Royal
179 Brompton Hospital (London, UK) were selected and subjected to TEVAR. These
180 patients were selected for TEVAR because of high co-morbidities and anatomic
181 suitability, e.g. aortic dimensions suitable to accommodate a ready-made
182 commercial stent-graft. All had elevated anesthetic risk score (American Society
183 of Anesthesiologists classification IV or greater), New York Heart Association
184 class III or IV, chronic lung disease and/or renal impairment. Decisions regarding
185 treatment required consensus between cardiac surgeons and cardiologists, with
186 the patients giving informed written consent. TEVAR in this setting was
187 approved by the internal review board of each center. All patients had EKG-gated
188 computed tomography (CT) (Figure 1) and echocardiography for the diagnosis
189 and assessment of aortic dissection. Echocardiography allowed assessment of
190 the aortic valve, left ventricular function, presence/absence of tamponade, and
191 interrogation of the supra-aortic vessels.

192

193 *TEVAR procedure*

194 Procedural planning was based on contrast-enhanced EKG-gated CT
195 (Figure 1), which was evaluated using standard software (TeraRecon, or
196 3Mensio) to select the appropriate stent-graft size; the diameter of the stent-
197 graft was chosen according to an estimate of the previous (before dissection)
198 aortic dimension to avoid oversizing. The stent-grafts used were usually ZENITH
199 TX2 (Cook, Bloomington, Indiana), GORE C-Tag (Gore Ltd. London, UK) or Relay
200 NBS (Bolton, Barcelona, Spain). They are made of a self-expanding nitinol stent
201 platform covered with polyester fabric. They are packed and mounted onto a
202 catheter-based delivery system. Figure 2 and Videos 1-3 show a typical TEVAR
203 procedure. With the patient under general anesthesia, a temporary pacing wire
204 was placed in the right ventricle and vascular access for the TEVAR device (22-

24F) obtained via right femoral arterial cut-down. The true lumen of the aorto-ilio-femoral arterial route was navigated using a soft long hydrophilic guide wire (Terumo, Inc.) protruding ahead of a pigtail catheter to reach the left ventricle under fluoroscopy and ultrasound guidance (transesophageal echocardiography) (26). Once the pigtail is in the left ventricle, the soft hydrophilic guide wire was exchanged to a stiff 270cm length guide wire through the pigtail catheter. The stiff guide wire has a soft spiral tip that sits within the left ventricular cavity. The stent-graft was then delivered along the stiff guide wire to its intended position, where its distal landing zone is between 'distal to the coronary ostia' and 'proximal to the brachiocephalic artery' in the ascending aorta. In this position, the distal tip of the delivery system may cross the aortic valve. For stent-graft deployment, rapid right ventricular pacing at 180 bpm was used to reduce the systolic blood pressure to ≤50mmHg in order to avoid displacement (windsock effect) of the stent-graft during its deployment, thus enabling its precise placement. At the end of the procedure, the temporary pacing wire was removed, the femoral artery access site closed, and the patient extubated and transferred to the coronary care unit. Procedural success was defined as successful placement of the stent-graft in its intended position with sealing of the entry tear.

Follow-up

Overall aortic and true lumen diameters were assessed at the level of sinotubular junction, ostium of the brachiocephalic artery and left subclavian artery. Follow-up CT scans were performed approximately at 6 months and then annually post TEVAR.

Statistical analysis

Descriptive statistic was used to characterize patients, procedural data and individual survival.

RESULTS

A total of 12 patients with proximal (type A) aortic dissection were

selected for TEVAR (Table 1). There were 10 DeBakey type II and 2 DeBakey type I dissections. The mean age ± standard deviation (SD) was 81 ± 7 years; male:female ratio was 9:3. All patients were of advanced age with chronic lung disease, coronary artery disease and/or renal impairment. The mean EuroSCORE II was 9.1 ± 4.5 (SD). The median time from onset of symptoms/diagnosis to TEVAR was 24 days. There were 6 cases of acute (≤14 days after symptom onset) and 6 cases of subacute (15 days to 3 months) or chronic (>3 months) aortic dissections. The false lumen of the dissection expanded significantly causing various complications, including dyspnoea, hoarseness or laryngeal nerve dysfunction. There was a history of chest and back pain in all cases. There were no significant aortic insufficiency, no clinically apparent distal malperfusion syndromes and no distal interventions required.

Procedural success was 91.7% (11/12) (Table 1). There was one death due to cardiac tamponade from wire induced perforation of the left ventricle. All remaining 11 patients were discharged alive within 2 weeks of TEVAR. The mean procedural time was 86 ± 33 (SD) minutes. Stent-grafts were deployed under rapid right ventricular pacing which achieved a mean systolic pressure of 34 ± 15 (SD) mmHg. The mean follow-up time was 21.1 ± 11.8 (SD) months (range 0 - 36 months) post TEVAR. There were 4 deaths, one each at 15, 19, 23 and 36 months (Table 1). All appeared to have died from natural causes. The mean survival in those who died during follow-up was 23 months.

Follow-up CT scans revealed thrombosis or remodelling of the stent-graft excluded false lumen. The diameter of the aorta at the sinotubular junction was not enlarged and remained similar to the normal aorta post TEVAR (Figure 3).

DISCUSSION

There is general consensus that proximal aortic dissection or any major pathology involving the ascending aorta should be subjected to surgical repair. However, 10-30% of patients with acute type A aortic dissection are considered too high risk for surgical repair and would therefore receive only medical therapy with associated high mortality of ≈60% in the intermediate term (13, 15, 27, 28). Surgical mortality is 10-25% (16, 27) depending on the complexity of the

operation and the clinical status of the patient. In our hands, the procedural mortality of TEVAR was 8%, which compares favorably with the published early endovascular mortality of 11% [18, 19]. Interestingly, the most anticipated complications such as major stroke did not occur. One minor stroke (transient) and one death from guidewire perforation of the left ventricle leading to fatal tamponade occurred.

We estimate the number of TEVAR procedures performed in this study relative to all emergency surgeries for type A aortic dissection in our 3 centers to be ≈2%, or 6-17% of inoperable type A cases (assuming the incidence of type A dissection ≈40 cases/year for a typical aortic center; therefore across 3 centers spanning the study period of 6 years, the total number of cases = 40 cases x 6 years x 3 centers = 720 cases; generally 10-30% of type A dissections are inoperable (15)).

Successful sealing of the false lumen entry with no development of proximal type I endoleak were achieved. During follow-up, no cases of endoleak were identified which is encouraging and different to ≈10% incidence reported elsewhere (29). In selecting the appropriate size of stent-grafts, we chose the diameter of the stent-grafts according to an estimate of the previous (before dissection) aortic dimension to avoid oversizing. The goal was to re-shape the dissected ascending aorta, cover the entry tear and depressurize the false lumen (30, 31); there is a fine balance between fixation to the aortic wall and the degree of intimal injury caused by the self-expanding stent-graft. However, once precisely deployed, the process of remodelling of the false lumen appears similar between the proximal and distal dissection, and takes place usually within one year, similar to that reported elsewhere (32, 33). Most of our cases were DeBakey type II dissections, and even in the 2 cases of type I dissection (patients 2 and 3 in Table 1), favorable aortic remodelling of the descending aorta were observed. It seems that the therapeutic concept of closing the entry and depressurizing the false lumen in type B (distal) aortic dissection holds true also in type A (ascending) aortic dissection (3, 4). As long as the false lumen is thrombosed and depressurized, survival even with type A aortic dissection can be improved by TEVAR (34). In addition, the patients' exposure to unacceptable risk of surgery is minimized.

Current literature (mostly single or small case series) underlines the feasibility of proximal endovascular procedures over more than 10 years, performed by surgeons and interventionalists (Table 2). Our series over 6 years with a mean follow-up of >20 months (range up to 3 years) underlines the fact that in the setting of significant co-morbidities representing high surgical risk but with suitable anatomy, TEVAR can be a viable alternative to surgical repair. In other words, it is feasible to avoid high risk/ complex surgery, and apply a less traumatic intervention to obtain a similar or better short-term outcome in a subset of elderly patients with significant co-morbidities. The advantages of TEVAR includes the avoidance of thoracotomy, cardiopulmonary bypass, selective head perfusion and associated surgical risks in an elderly population, often in a critical condition (35). If the high initial ≈60% mortality of type A aortic dissection can be successfully lowered by TEVAR, such less traumatic strategy may potentially become an option in a broader spectrum of patients (27). As TEVAR is a fairly expensive procedure, its associated lower risks/complications and shorter lengths of hospital stay compared to surgery may potentially demonstrate its advantages in terms of cost and clinical outcome over surgery.

TEVAR will not be feasible in every patient; the most suitable anatomy is where the entry tear of the dissection is located in the middle portion of the ascending aorta. Entry tears close to the coronaries or aortic valve lack a suitable length of landing zone. Entry tears close to the brachiocephalic artery would require complex branching/fenestration strategies. Currently, only a limited number of choices are available regarding the type of stent-graft and delivery system because relatively large diameter and short length stent-grafts are required. Existing delivery systems need to be modified for ascending aorta intervention: a long nosecone can either damage the aortic valve or increase the chance of left ventricular perforation by the stiff guidewire, as occurred in one of our patients.

On a technical note, with the use of rapid ventricular pacing no misplacement of these short stent-grafts was seen. Pacing is probably the most efficient method to avoid windsock effect of the left ventricle, enabling precise stent-graft placement. Transoesophageal echocardiography is also useful in

guiding stent- graft positioning and assessing sealing of the entry tear (26).

It should be emphasized that a multidisciplinary team, consisting of cardiac and vascular surgeons and cardiologists, should select suitable patients for the procedure, similar to transcatheter aortic valve replacement (TAVR). Looking forward, we believe TEVAR in the ascending aorta is a definitive solution for patients not accepted for surgery, or a bridging solution in case of unclear neurological diagnosis (e.g., major stroke) to buy time for reconstructive surgery. Selection process in patients not suitable for surgical valve replacement may even be conceivable for combined TAVR- TEVAR technology, in an attempt to treat variants of aortic dissection including those with compromised aortic valve function. It should also be emphasised that in the acute setting there is a need to identify and transfer type A aortic dissection patients to a specialized unit as quickly as possible; once the dissection has produced coronary obstruction (usually the right coronary artery) with ensuing (right) ventricular infarction and heart failure, it is a difficult situation to retrieve by either endografting or conventional surgery.

Study limitations

While we could demonstrate proof of concept and feasibility of TEVAR in the ascending aorta with encouraging results, we did not examine possible detrimental effects such as stiffening of the ascending aorta by the stent, lowered vascular compliance, negative effects on the aortic valve function or hypertension in this observational study. Our sample size is relatively small, but it represents one of the biggest case-series in the field and supports the feasibility of TEVAR in practical terms. We have no control group (medically treated or surgery) for comparison, but historical data suggests that surgery confers 25% peri-operative mortality, and medical treatment is associated with 60% mortality (13, 15, 27, 28). A propensity-matched comparison prior to any randomized study would probably be the next step to strengthen the data on TEVAR in the proximal aorta; current technology is unlikely to allow a broader application yet.

Conclusion

TEVAR is feasible and reveals promising early results in selected patients

with proximal (type A) aortic dissection who are poor candidates for surgical repair. The current iteration of stent-graft technology however needs to be adapted to the specific features of the ascending aorta before TEVAR as a concept emerges for broader applications in the proximal aorta.

Figure legends

Figure 1. From top to bottom: 2-dimensional transverse and coronal section of a localized proximal aortic dissection (type A) with a large entry between the aortic valve and brachiocephalic artery; 3-dimensional reconstruction prior to treatment.

Figure 2. TEVAR procedural sequence for placing a covered stent-graft to treat a type A aortic dissection. (A) Aortogram and set-up showing a right ventricular pacing wire and transesophageal echo probe; (B) Stent-graft deployment during rapid pacing; (C) Completed deployment of the stent-graft; (D) Aortogram demonstrating procedural success.

Figure 3. From top to bottom: 2-dimensional transverse and coronal sections of a proximal (type A) aortic dissection before (left) and after stent-grafting (right), demonstrating TEVAR reconstruction and remodelling of the aorta. The bottom panels demonstrate the successful intervention in 3-dimensional reconstruction.

Video 1. Before TEVAR. Digital subtraction angiogram showing a large tear in the ascending aorta, and a marker pigtail, pacing wire and transoesophageal echocardiography probe in place.

Video 2. During TEVAR. Fluoroscopic display of the launch of a self-expanding Viabahn stent-graft in the brachiocephalic artery followed by a self-expanding C-Tag stent-graft covering the ascending aorta under rapid pacing.

Video 3. After TEVAR. Completion angiogram after placement of the Viabahn stent-graft in the brachiocephalic artery and C-Tag stent-graft in the ascending aorta; the entry to the dissection is sealed and flow is preserved to the brachiocephalic and coronary arteries.

References

1. Suenaga E, Sato M, Fumoto H. Ascending aortic replacement for acute type A aortic dissection in octogenarians. Gen Thorac Cardiovasc Surg 2016 Mar;64(3):138-43.
2. Rylski B, Hoffmann I, Beyersdorf F, et al. Acute aortic dissection type A: age-related management and outcomes reported in the German Registry for Acute Aortic Dissection Type A (GERAADA) of over 2000 patients. Ann Surg 2014 Mar;259(3):598-604.
3. Nienaber CA, Fattori R, Lund G, et al. Nonsurgical reconstruction of thoracic aortic dissection by stent-graft placement. N Engl J Med 1999 May 20;340(20):1539-45.
4. Dake MD, Kato N, Mitchell RS, et al. Endovascular stent-graft placement for the treatment of acute aortic dissection. N Engl J Med 1999 May 20;340(20):1546-52.
5. Resch TA, Delle M, Falkenberg M, et al. Remodeling of the thoracic aorta after stent grafting of type B dissection: a Swedish multicenter study. J Cardiovasc Surg (Torino) 2006 Oct;47(5):503-8.
6. Eggebrecht H, Nienaber CA, Neuhauser M, et al. Endovascular stent-graft placement in aortic dissection: a meta-analysis. Eur Heart J 2006 Feb;27(4):489-98.
7. Fattori R, Nienaber CA, Rousseau H, et al. Results of endovascular repair of the thoracic aorta with the Talent Thoracic stent graft: the Talent Thoracic Retrospective Registry. J Thorac Cardiovasc Surg 2006 Aug;132(2):332-9.
8. Hassoun HT, Matsumura JS. The COOK TX2 thoracic stent graft: preliminary experience and trial design. Semin Vasc Surg 2006 Mar;19(1):32-9.
9. Kwolek CJ, Fairman R. Update on thoracic aortic endovascular grafting using the medtronic talent device. Semin Vasc Surg 2006 Mar;19(1):25-31.
10. Makaroun MS, Dillavou ED, Kee ST, et al. Endovascular treatment of thoracic aortic aneurysms: results of the phase II multicenter trial of the GORE TAG thoracic endoprosthesis. J Vasc Surg 2005 Jan;41(1):1-9.

437 11. Szeto WY, McGarvey M, Pochettino A, et al. Results of a new surgical
438 paradigm: endovascular repair for acute complicated type B aortic dissection.
439 Ann Thorac Surg 2008 Jul;86(1):87-93; discussion -4.
440 12. Santini F, Montalbano G, Casali G, et al. Clinical presentation is the main
441 predictor of in-hospital death for patients with acute type A aortic dissection
442 admitted for surgical treatment: a 25 years experience. Int J Cardiol 2007 Feb
443 14;115(3):305-11.
444 13. Centofanti P, Flocco R, Ceresa F, et al. Is surgery always mandatory for
445 type A aortic dissection? Ann Thorac Surg 2006 Nov;82(5):1658-63; discussion
446 64.
447 14. Akin I, Nienaber C. [Established Indications for Invasive Treatment of
448 Thoracic Aortic Aneurysm]. Dtsch Med Wochenschr 2015 Nov;140(23):1747-52.
449 15. Pape LA, Awais M, Woznicki EM, et al. Presentation, Diagnosis, and
450 Outcomes of Acute Aortic Dissection: 17-Year Trends From the International
451 Registry of Acute Aortic Dissection. J Am Coll Cardiol 2015 Jul 28;66(4):350-8.
452 16. Trimarchi S, Nienaber CA, Rampoldi V, et al. Contemporary results of
453 surgery in acute type A aortic dissection: The International Registry of Acute
454 Aortic Dissection experience. J Thorac Cardiovasc Surg 2005 Jan;129(1):112-22.
455 17. Shah A, Coulon P, de Chaumaray T, et al. Novel technique: staged hybrid
456 surgical and endovascular treatment of acute Type A aortic dissections with
457 aortic arch involvement. J Cardiovasc Surg (Torino) 2006 Oct;47(5):497-502.
458 18. Diethrich EB, Ghazoul M, Wheatley GH, et al. Surgical correction of
459 ascending type a thoracic aortic dissection: simultaneous endoluminal exclusion
460 of the arch and distal aorta. J Endovasc Ther 2005 Dec;12(6):660-6.
461 19. Dobrilovic N, Elefteriades JA. Stenting the descending aorta during repair
462 of type A dissection: technology looking for an application? J Thorac Cardiovasc
463 Surg 2006 Apr;131(4):777-8.
464 20. Moon MC, Greenberg RK, Morales JP, et al. Computed tomography-based
465 anatomic characterization of proximal aortic dissection with consideration for
466 endovascular candidacy. J Vasc Surg 2011 Apr;53(4):942-9.
467 21. Sobocinski J, O'Brien N, Maurel B, et al. Endovascular approaches to acute
468 aortic type A dissection: a CT-based feasibility study. Eur J Vasc Endovasc Surg
469 2011 Oct;42(4):442-7.

470 22. Ihnken K, Sze D, Dake MD, Fleischmann D, Van der Starre P, Robbins R.
471 Successful treatment of a Stanford type A dissection by percutaneous placement
472 of a covered stent graft in the ascending aorta. J Thorac Cardiovasc Surg 2004
473 Jun;127(6):1808-10.
474 23. Wang ZG, Massimo CG, Li M, et al. Deployment of endograft in the
475 ascending aorta to reverse type A aortic dissection. Asian J Surg 2003
476 Apr;26(2):117-9.
477 24. Zhang H, Li M, Jin W, Wang Z. Endoluminal and surgical treatment for the
478 management of Stanford Type A aortic dissection. Eur J Cardiothorac Surg 2004
479 Oct;26(4):857-9.
480 25. Zimpfer D, Czerny M, Kettenbach J, et al. Treatment of acute type a
481 dissection by percutaneous endovascular stent-graft placement. Ann Thorac
482 Surg 2006 Aug;82(2):747-9.
483 26. Koschyk DH, Nienaber CA, Knap M, et al. How to guide stent-graft
484 implantation in type B aortic dissection? Comparison of angiography,
485 transesophageal echocardiography, and intravascular ultrasound. Circulation
486 2005 Aug 30;112(9 Suppl):I260-4.
487 27. Rampoldi V, Trimarchi S, Eagle KA, et al. Simple risk models to predict
488 surgical mortality in acute type A aortic dissection: the International Registry of
489 Acute Aortic Dissection score. Ann Thorac Surg 2007 Jan;83(1):55-61.
490 28. Tsai TT, Evangelista A, Nienaber CA, et al. Long-term survival in patients
491 presenting with type A acute aortic dissection: insights from the International
492 Registry of Acute Aortic Dissection (IRAD). Circulation 2006 Jul 4;114(1
493 Suppl):I350-6.
494 29. Ueda T, Fleischmann D, Dake MD, Rubin GD, Sze DY. Incomplete endograft
495 apposition to the aortic arch: bird-beak configuration increases risk of endoleak
496 formation after thoracic endovascular aortic repair. Radiology 2010
497 May;255(2):645-52.
498 30. Ye C, Chang G, Li S, et al. Endovascular stent-graft treatment for Stanford
499 type A aortic dissection. Eur J Vasc Endovasc Surg 2011 Dec;42(6):787-94.
500 31. Metcalfe MJ, Karthikesalingam A, Black SA, Loftus IM, Morgan R,
501 Thompson MM. The first endovascular repair of an acute type A dissection using
502 an endograft designed for the ascending aorta. J Vasc Surg 2012 Jan;55(1):220-2.

503 32. Lu Q, Feng J, Zhou J, et al. Endovascular repair of ascending aortic
504 dissection: a novel treatment option for patients judged unfit for direct surgical
505 repair. J Am Coll Cardiol 2013 May 7;61(18):1917-24.
506 33. Ronchey S, Serrao E, Alberti V, et al. Endovascular stenting of the
507 ascending aorta for type A aortic dissections in patients at high risk for open
508 surgery. Eur J Vasc Endovasc Surg 2013 May;45(5):475-80.
509 34. Bossone E, Evangelista A, Isselbacher E, et al. Prognostic role of
510 transesophageal echocardiography in acute type A aortic dissection. Am Heart J
511 2007 Jun;153(6):1013-20.
512 35. Comas GM, Leshnower BG, Halkos ME, et al. Acute type a dissection:
513 impact of antegrade cerebral perfusion under moderate hypothermia. Ann
514 Thorac Surg 2013 Dec;96(6):2135-41.
515
516

Table 1

Patient	Age & Sex	Diagnosis	Euroscore II	SG	SG size DxL (mm)	Procedure duration (min)	Procedural complications	Follow-up (months)
1	74 M	cTAAD (DeBakey II)	6.9	Cook	34x77	90	None	32
2	75 M	aTAAD (DeBakey I)	8.1	Bolton NBS	34x60	140	None	29
3	87 M	aTAAD (DeBakey I)	13.4	Bolton NBS	34x60	79	None	35
4	89 M	cTAAD (DeBakey II)	15.0	Cook	36x77	149	None	15, †
5	90 M	cTAAD (DeBakey II)	19.3	Cook	36x77	70	Ventricular rupture, tamponade	0, †
6	69 M	aTAAD (DeBakey II)	3.9	Cook	34x77	61	None	36, †
7	75 M	cTAAD (DeBakey II)	4.9	Bolton NBS	34x60	70	None	24
8	87 M	cTAAD (DeBakey II)	9.4	Cook	36x77	49	Minor Stroke	15
9	87 F	aTAAD (DeBakey II, post TAVR)	7	Optimed	32x50	120	None	23, †
10	83 M	cTAAD (DeBakey II)	6.9	Cook	34x77	89	None	19, †
11	75 F	aTAAD (DeBakey II)	5.9	Cook	34x77	60	none	5
12	75 F	aTAAD (DeBakey II)	8.9	Gore + Viabahn in innominate artery	34x100	60	none	0

Abbreviations: aTAAD (acute type A aortic dissection), cTAAD (subacute or chronic type A aortic dissection), D (diameter), F (female), L (length), M (male), NBS (non-bare stent), SG (stent-graft), TAVR (transcatheter aortic valve replacement). † indicates deceased.

Table 2

Author	Year	N	Acute n (%)	Stent-graft	Access route	Follow-up months	Early mortality n (%)	Cause of death	Complications	Re-intervention
Dorros et al	2000	1	1 (100)	Lecteba	RFV Trans-septal	1	1 (100)	Cardiac arrest	-	-
Wang et al	2003	1	1 (100)	Covered Z-stent	Aorta	12	0	-	-	-
Ihnken et al	2004	1	1 (100)	Gore	-	none	0	-	-	-
Zhang et al	2004	1	0	Gianturco Z-stent	TF	21	0	-	Aortic regurgitation	Open surgery
Zimpfer et al	2006	1	1 (100)	Jotec	TF	1	0	-	-	-
Senay et al	2007	1	1 (100)	Medtronic	TF	none	0	-	Endoleak	-
Palma et al	2007	1	0	Braile Biomed	TF	none	1 (100)	Cardiac arrest stent migration	-	-
Ye et al	2011	10	6 (60)	Various	2 LCCA, 8 TF	35.5	1 (10)	Gastrointestinal bleeding	-	Balloon dilatation for endoleak
Metcalfe e al	2012	1	1 (100)	Medtronic	TF	none	0	-	-	-
Gustavo et al	2012	1	1 (100)	Cook	Aorta	32	0	-	Tachycardia	-
Ronchey et al	2013	4	4 (100)	Cook	TF	15 (4-39)	0	-	-	-
Bahaeddin et al	2013	1	0	Cook	TA	1	0	-	Aortic regurgitation	-
Eric et al	2013	1	1 (100)	Cook	TA	none	0	-	-	-
Kölbel et al	2013	1	1 (100)	Cook	TA	6	0	-	-	-
Frederic et al	2013	1	1 (100)	Jotec	TA	none	0	-	-	-
Lu et al	2013	15	5 (33)	Cook	-	22 (12-31)	0	-	Arrhythmia	Angioplasty and stenting of left renal artery
Yuuya et al	2014	1	1 (100)	Gore	RCA	none	0	-	-	-
Kimberly et al	2014	1	1 (100)	Medtronic	TF	none	0	-	-	-
Vallabhajosyula et al	2015	6	3 (50)	Cook Amplatzer	4 TA, 1 TF, 1 LCCA	33 (3-57)	0	-	Endoleak Stroke	Re-stenting for endoleak
Roselli et al	2015	18	9 (50)	Cook, Gore, Medtronic	5 TA, 4 TAx, 9 TF	12 median	3 (17)	Coronary obstruction, aortic rupture, tamponade	Contained aortic rupture, endoleak, stent migration, apical PA	Stent extension, open surgery

Abbreviations: LCCA (left common carotid artery), N (number), PA (pseudoaneurysm), RCA (right carotid artery), RFV (right femoral vein), TA (transapical), TAx (transaxillary), TF (transfemoral).

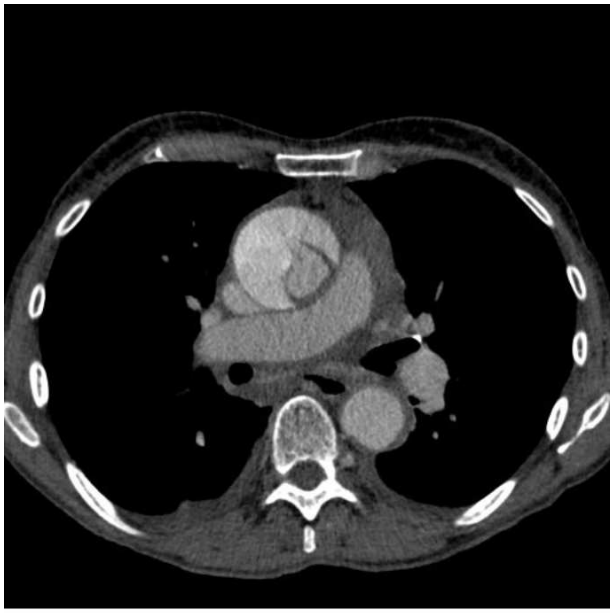

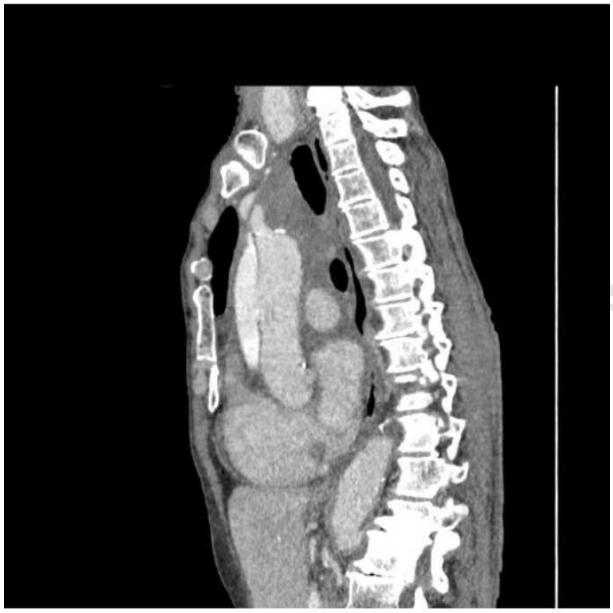

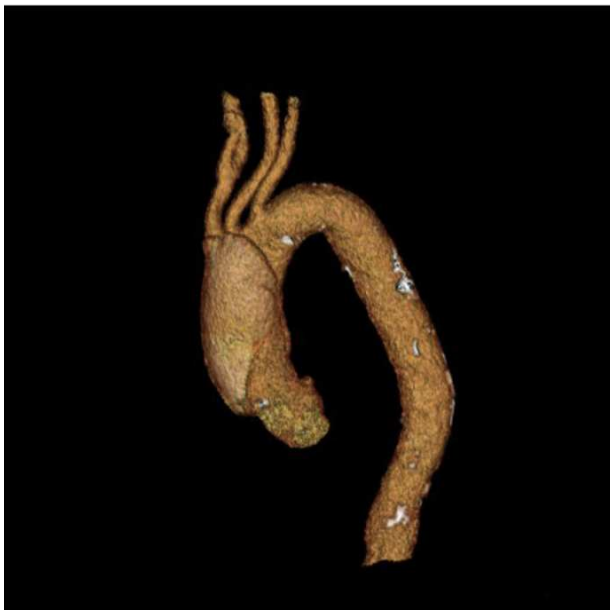

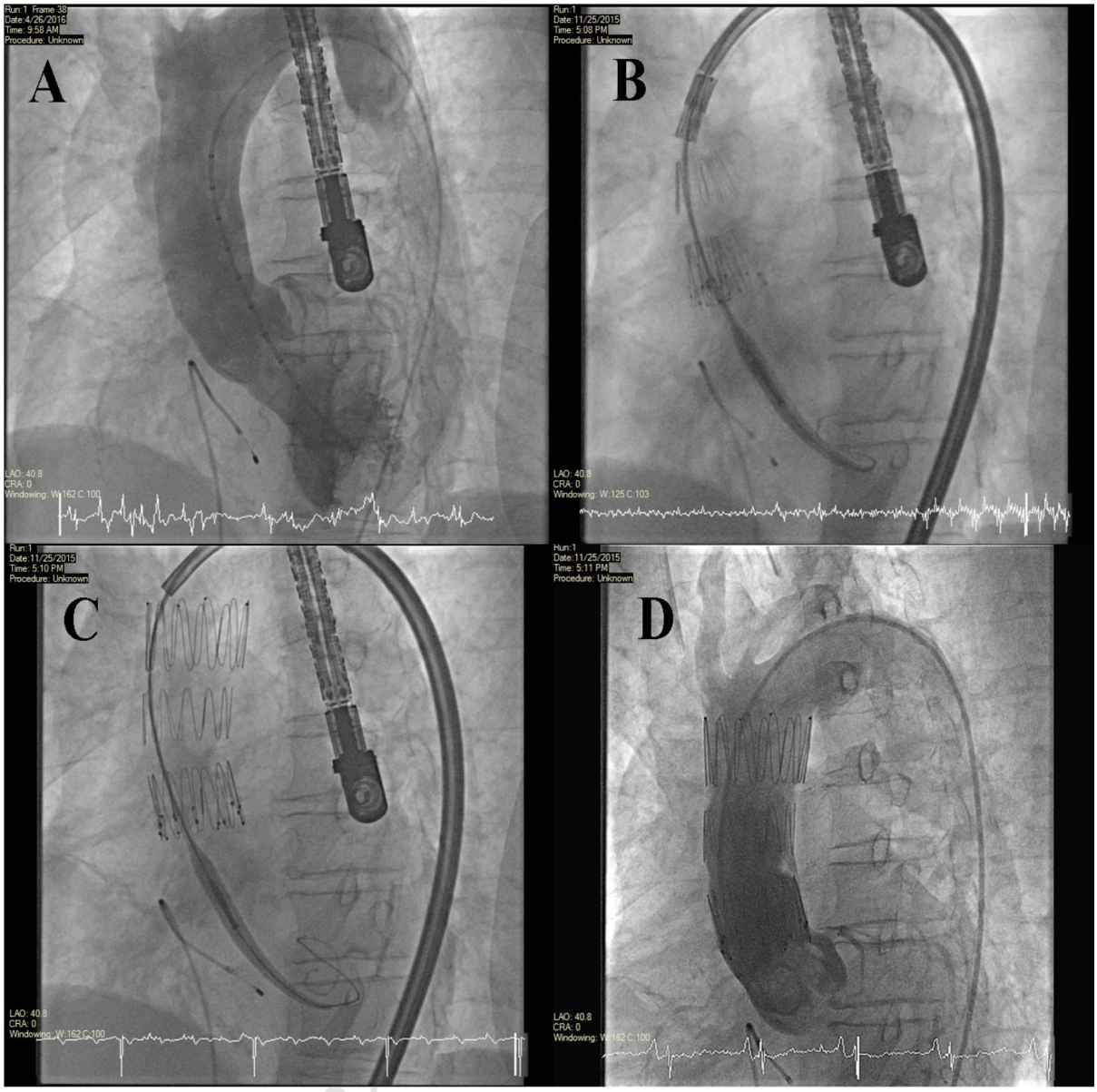
A
Run:1 Frame 38
Date:4/26/2016
Time: 3:58 AM
Procedure: Unknown
LAO: 40.8
CRA: 0
Windowing: W:162 C:100
B
Run:1
Date:11/25/2015
Time: 5:08 PM
Procedure: Unknown
LAO: 40.8
CRA: 0
Windowing: W:125 C:103
C
Run:1
Date:11/25/2015
Time: 5:10 PM
Procedure: Unknown
LAO: 40.8
CRA: 0
Windowing: W:162 C:100
D
Run:1
Date:11/25/2015
Time: 5:11 PM
Procedure: Unknown
LAO: 40.8
CRA: 0
Windowing: W:162 C:100

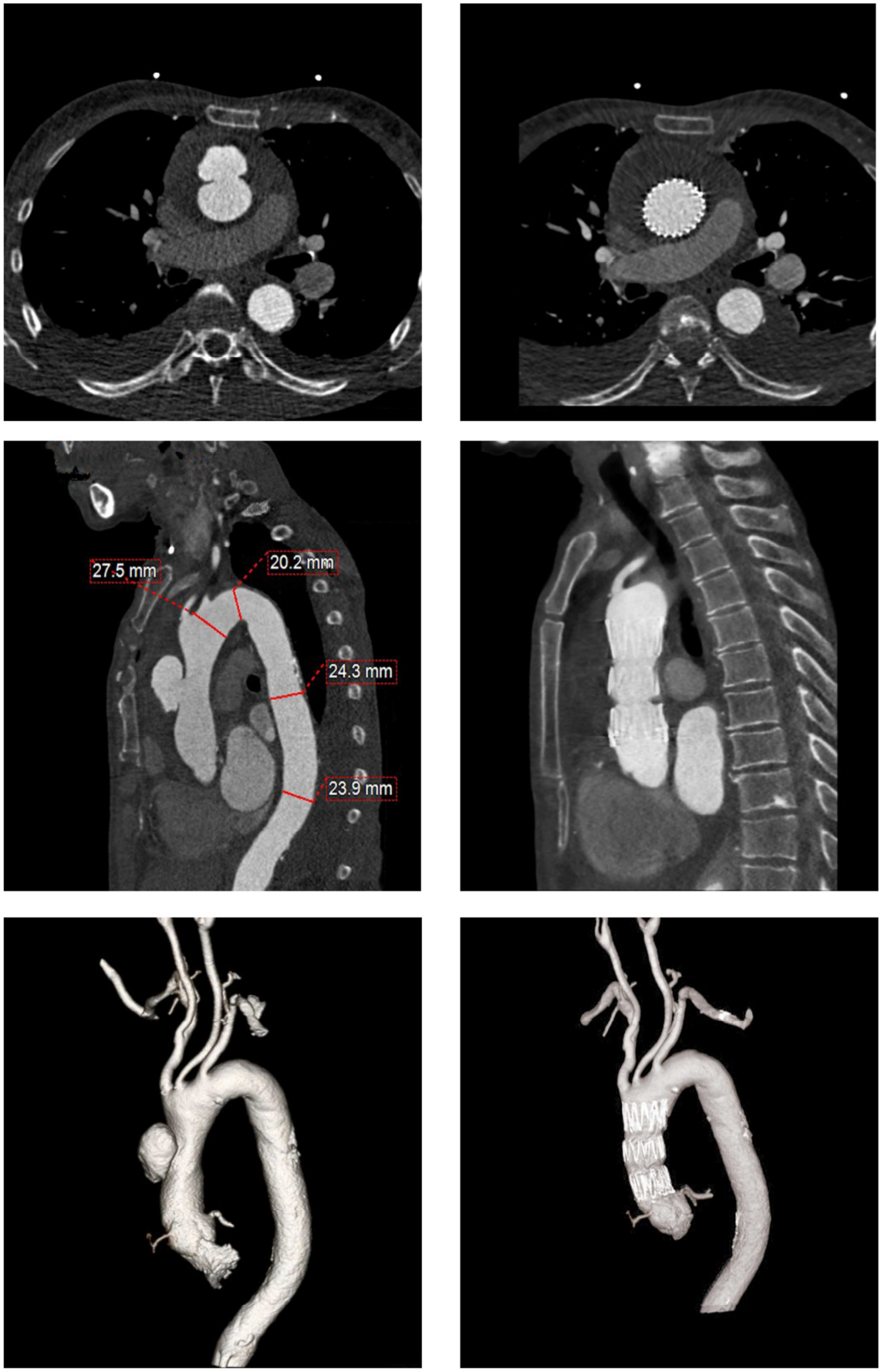
27.5 mm
20.2 mm
24.3 mm
23.9 mm