Author's Accepted Manuscript



www.elsevier.com/locate/journal

Comparative Multimodal Meta-Analysis of Structural and Functional Brain Abnormalities in Autism Spectrum Disorder and Obsessive-Compulsive DisorderComparative Neuroimaging Meta-Analysis of ASD and OCD

Christina O. Carlisi, Luke J. Norman, Steve S. Lukito, Joaquim Radua, David Mataix-Cols, Katya Rubia

PII: S0006-3223(16)32914-6
DOI: http://dx.doi.org/10.1016/j.biopsych.2016.10.006
Reference: BPS13020

To appear in: *Biological Psychiatry*

Received date: 8 March 2016
Revised date: 3 October 2016
Accepted date: 5 October 2016

Cite this article as: Christina O. Carlisi, Luke J. Norman, Steve S. Lukito, Joaquim Radua, David Mataix-Cols and Katya Rubia, Comparative Multimodal Meta-Analysis of Structural and Functional Brain Abnormalities in Autism Spectrum Disorder and Obsessive-Compulsive DisorderComparative Neuroimaging Meta-Analysis of ASD and OCD, *Biological Psychiatry,* http://dx.doi.org/10.1016/j.biopsych.2016.10.006

Comparative multimodal meta-analysis of structural and functional brain abnormalities in autism spectrum disorder and obsessive-compulsive disorder

Carlisi, Christina O[1], Norman, Luke J[1], Lukito, Steve S[1], Radua, Joaquim[2,3,4], MD BStat PhD, Mataix-Cols, David[2], PhD CPsychol, Rubia, Katya[1], PhD

[1]Department of Child and Adolescent Psychiatry, Institute of Psychology, Psychiatry and Neuroscience, King's College London, [2]Department of Clinical Neuroscience, Centre for Psychiatry Research, Karolinska Institutet, Stockholm, Sweden, [3]FIDMAG Germanes Hospitalàries, CIBERSAM, Barcelona, Spain, [4]Department of Psychosis Studies, Institute of Psychiatry, Psychology & Neuroscience, King's College London, London, England

Short Title: Comparative neuroimaging meta-analysis of ASD and OCD

Correspondence to:

Prof Katya Rubia

Department of Child and Adolescent Psychiatry/MRC Social, Genetic and Developmental Psychiatry (SGDP) Centre, PO46, Institute of Psychiatry, Psychology and Neuroscience, King's College London, 16 DeCrespigny Park, London, SE5 8AF, UK

Tel: 0044-207-8480463

Fax: 0044-207-2085800

Email: katya.rubia@kcl.ac.uk

Keywords: OCD, Autism, cognitive control, meta-analysis, VBM, fMRI

Abstract

Objective: Autism spectrum disorder (ASD) and obsessive-compulsive disorder (OCD) share inhibitory control deficits possibly underlying poor control over stereotyped/repetitive and compulsive behaviours, respectively. However, it is unclear whether these symptom profiles are mediated by common or distinct neural profiles. This comparative multimodal meta-analysis assessed shared and disorder-specific neuroanatomy and neurofunction of inhibitory functions.

Methods: A comparative meta-analysis of 62 voxel-based morphometry (VBM) and 26 functional magnetic resonance imaging (fMRI) studies of inhibitory control was conducted comparing grey matter volume (GMV) and activation abnormalities between ASD (sMRI:911;fMRI:188) and OCD (sMRI:928;fMRI:247) patients versus controls. Multimodal meta-analysis compared groups across VBM and fMRI.

Results: Both disorders shared reduced function and structure in rostral/dorsomedial prefrontal cortex including anterior cingulate. OCD had disorder-specific increase in structure and function of left basal ganglia (BG)/insula relative to controls and ASD, who had reduced right BG/insula volumes versus OCD. In fMRI, ASD patients showed disorder-specific reduced left dorsolateral-prefrontal activation and reduced posterior cingulate deactivation, while OCD patients showed temporo-parietal underactivation.

Conclusions: The multimodal comparative meta-analysis shows shared and disorder-specific abnormalities. While rostro-dorsomedial prefrontal cortex was smaller in structure and function in both disorders, this was concomitant with increased structure and function in BG/insula in OCD, but a reduction in ASD, presumably reflecting a disorder-specific fronto-striato-insular dysregulation in OCD in the form of poor frontal control over overactive BG, and a fronto-striato-insular maldevelopment in ASD with reduced structure and function in this network. Disorder-differential mechanisms appear to drive overlapping phenotypes of inhibitory control abnormalities in ASD and OCD.

INTRODUCTION

Autism spectrum disorder (ASD) is a predominantly male neurodevelopmental disorder characterised by difficulties in reciprocal social-communication and stereotyped repetitive behaviours(1) with a prevalence of 0.6-1%(2).

Obsessive-compulsive disorder (OCD) is characterized by recurrent intrusive and distressing thoughts (obsessions) and repetitive mental and behavioural rituals (compulsions)(1), affecting 1-3% of the population, with a slightly higher prevalence among paediatric males and adult females(3).

Both disorders are highly heterogeneous(4), carry more than 25% comorbidity with one another(5) and can be clinically difficult to separate. Both disorders are thought to be associated with poor top-down behavioural and neurocognitive inhibitory control(6), which may underlie poor control over stereotyped repetitive behaviours in ASD(7) and compulsions and intrusive thoughts in OCD(8). Inhibitory control is typically measured in motor and interference inhibition or switching tasks(9). Motor response inhibition tasks including go/no-go (GNG) and stop tasks measure selective inhibition or withdrawal of a built-up pre-potent response to frequent stimuli after presentation of an infrequent no-go or stop signal, respectively(10). Stroop, Simon or Erikson flanker interference inhibition tasks measure the ability to inhibit a pre-potent response tendency that conflicts with the primary intended action, while switching measures the ability to inhibit previously valid stimulus-response associations to engage in new ones(10). While in Stop, GNG and interference inhibition tasks, a pre-potent motor response has to be inhibited, switching requires, in addition to motor inhibition, reengagement in a different response. However, all these tasks share inhibitory processes(11) which are mediated in adults and children by overlapping inferior and medial fronto-striato-thalamo-parietal networks, including ventrolateral prefrontal cortex (VLPFC)/anterior insula, supplementary motor (SMA), anterior cingulate cortex (ACC), caudate, subthalamic nucleus, and inferior parietal lobe (IPL)(11-15). Both OCD(8,16,17) and ASD(18-20) have deficits in performance

and fronto-striato-parietal activation during these inhibitory control tasks, suggesting that impaired inhibition could be a trans-diagnostic behavioural phenotype.

In ASD, functional magnetic resonance imaging (fMRI) studies of motor/cognitive interference inhibition and switching report abnormalities in fronto-striato-parietal areas including DLPFC and VLPFC(19,21-23), r/dACC/MPFC(24,25), insula(23,26,27), parietal regions(19,28) and caudate(22,24), as also shown in meta-analyses of non-social processes that included inhibitory control tasks(17,29,30). Structural meta-analyses of GMV in ASD implicate fronto-limbic and fronto-parietal abnormalities, reporting decreased GMV in cerebellar, hippocampal, amygdala and parietal regions but increased GMV in superior frontal, striatal and temporal regions(31-33), with basal ganglia (BG) abnormalities associated with symptom severity(34).

FMRI studies of response/interference inhibition and switching in children and adults with OCD have consistently shown hypoactivation in rostral and dorsal ACC and medial prefrontal cortex (r/dACC/MPFC), VLPFC and dorsolateral prefrontal cortex (DLPFC) as well as altered striatal activation(16,35), supported by a recent meta-analysis and review(8,18). Structural meta- and mega-analyses of whole-brain voxel-based morphometry (VBM) studies in OCD report decreased grey matter volumes (GMV) in r/dACC/MPFC and ventromedial orbitofrontal cortex (vmOFC) but increased GMV in bilateral striatum(18,36-38), which furthermore has been linked to poor inhibitory performance, suggesting fronto-striatal dysregulation(39).

Despite apparent overlap in frontal and striatal abnormalities between the two disorders, no neuroimaging studies have directly compared ASD and OCD patients. Given the similarities in clinical phenotypes between these disorders(6), establishing common and distinct neuroanatomical and neurofunctional biomarkers may help with future differential diagnosis and treatment development.

The aim of this study was therefore to investigate whether a common behavioural phenotype may be underpinned by common and/or distinct neural signatures in the two disorders.

For this purpose, we conducted a quantitative meta-analysis comparing OCD and ASD in brain function/structure abnormalities using whole-brain VBM and fMRI studies of inhibitory control, and compared multimodal structural and functional neural abnormalities.

We hypothesized that OCD patients would show disorder-specific fronto-striatal dysregulation, i.e. increased BG but decreased ventromedial and r/dACC/MPFC GMV activation(8,36), while ASD patients would show disorder-specific reductions in lateral fronto-striato-limbic volumes and activations(31,32). We further predicted shared underactivation and reduced structure in medial prefrontal regions(18,24,25).

METHODS AND MATERIALS

Study selection

A comprehensive literature search was conducted by CC, SL and LN through December 2015 for whole-brain imaging studies using VBM or fMRI of inhibitory control in paediatric and adult ASD and OCD (using stop, go/no-go, Simon, Stroop, Eriksen Flanker or switching tasks). For details and search terms see Supplement. Studies meeting the following criteria were included: (1) comparison with a control group (2) for fMRI, use of a task investigating inhibitory control (see above), (3) included minimum 10 patients, (4) used standardised measures to assess OCD or ASD, (5) reported sufficient information to calculate effect-sizes (i.e. software/coordinates for relevant contrasts) and (6) within one study, used the same significance/extent threshold throughout the whole brain in all analyses. Authors were contacted for additional information if necessary. Studies were excluded if they (1) used region-of-interest (ROI) approaches, (2) did not perform statistical comparisons between cases and controls and (3) did not report peak coordinates for relevant contrasts. ROI approaches may be more appropriate than whole-brain investigations when researchers are interested in the activation of a specific brain region. However, ROI studies were excluded from this meta-analysis because when conducting a *voxel-wise whole-brain* meta-analysis, inclusion of ROI analyses would bias the results, as voxels within ROIs would be set to have the effect-sizes reported

in the papers whereas the voxels in the rest of the brain would be *unfairly* set to have no effect-size. The exclusion of ROI studies is therefore recommended practice in structural and functional MRI whole-brain meta-analyses (see e.g. 31,36,40-50). MOOSE guidelines for meta-analyses of observational studies were followed(51). To avoid duplication, conjunctive group differences across tasks/conditions or main group effects across task conditions were excluded. Peak coordinates and effect-sizes of significant activation differences between patients and controls (or statistical maps where possible) were extracted from contrasts of interest for each study.

Statistical Methods

Meta-analyses of regional differences in activation or GMV were conducted using voxel-wise anisotropic effect-size Seed-based *d* Mapping (AES-SDM; http://www.sdmproject.com). Methods employed by SDM are described elsewhere(47,52) and summarized briefly here. SDM uses reported peak coordinates and effect-sizes from each study to recreate effect-size maps and an effect-size variance map of the signed (positive/negative) GMV or activation differences between patients and controls, converting the *t*-value of each peak to Hedges effect-size and applying an anisotropic non-normalized Gaussian kernel so voxels more correlated with the peak have higher effect-sizes. All maps were combined with a standard random-effects model, accounting for sample size, intra-study variability and between-study heterogeneity(53). Statistical significance was determined by permutation tests and default thresholds(52).

Some studies included different fMRI tasks in identical or largely overlapping samples(27,54-56), or compared patient subgroups to the same controls(57,58). To address this, SDM was modified to allow calculation of a single, combined map with reduced variance for such studies to avoid dependent data in analyses (see Supplement).

Separate analyses within each patient group were first performed to examine GMV and activation differences compared to their respective controls. Then, a quantitative comparison of

abnormalities in GMV and activation between ASD and OCD relative to controls was conducted by calculating the difference between each patient group across each voxel and using randomization tests to establish significance.

Meta-regressions were conducted within the OCD group(47) to examine effects of antidepressants on GMV and fMRI abnormalities. Most ASD patients were not receiving medication or insufficient information was provided.

Areas of shared abnormalities between patient groups versus controls within each modality were determined in conjunction analyses by computing *p*-value overlap within each voxel from the original meta-analytic maps accounting for error(59). This method was similarly used to perform multimodal analyses showing overlapping functional and structural abnormalities within each patient group relative to controls. Conjunction analysis determined overlapping (or distinct) regions between patient groups across both modalities.

The inclusion of several paradigms to assess inhibitory control introduces task-related heterogeneity. Given that there were not sufficient studies (minimum 10 studies recommended for SDM meta-analyses(47)) to conduct subgroup analyses by task-type, a supplementary meta-analysis was performed covarying for task-type (response/interference inhibition, switching).

Default SDM thresholds were used (voxel $p<.005$;peak height $z=1$;cluster extent=10 voxels); a threshold of $p<.0005$ was used for meta-regressions, and only regions found in the main between-group analysis were included(47,53). Jackknife sensitivity analyses were conducted to establish reproducibility of results by iteratively repeating analyses, excluding one dataset each time(47). Funnel plots and Egger's tests were conducted to detect abnormalities in results, e.g. conflicting studies or publication bias.

RESULTS

Included studies

Included were 32 VBM studies comparing ASD individuals to controls (ASD=911;Controls=932), 30 VBM studies comparing OCD patients to controls (OCD=928;Controls=942), 12 inhibitory control fMRI studies comparing ASD patients to controls (ASD=188;Controls=196) and 14 fMRI studies comparing OCD patients to controls (OCD=247;Controls=244) (**Table 1** and Supplement).

Group differences in demographics

Across all studies, patients were age and sex-matched to controls. Compared to OCD, ASD VBM [patients: $F(1,61)=42$, $p<.001$;controls: $F(1,61)=37$, $p<.001$] and fMRI studies [patients: $F(1,25)=18$, $p<.001$;controls: $F(1,25)=19$, $p<.001$] included more males. In the VBM meta-analysis, ASD patients were younger than OCD patients [$F(1,61)=19$, $p<.001$] (corresponding controls [$F(1,61)=21$, $p<.001$]). Across fMRI studies, patients [$F(1,18)=.1$, $p=.71$] and controls [$F(1,16)=.3$, $p=.56$] were matched on IQ, but too few VBM studies reported IQ scores to include this analysis (**Table 2A**).

To ensure group differences were not due to sex/age differences, comparative VBM and fMRI meta-analyses were covaried with sex, and only the comparative VBM meta-analysis was additionally covaried with age (as groups were age-matched in the fMRI comparison). In addition, the comparative meta-analyses were repeated on age and sex-matched subgroups (**Table 2B**). In this analysis, group-differences were minimized to the point of losing significance (*p*-values>0.5;any mild effect would reach significance given the size of the overall samples) (see Supplement).

Last, the proportion of fMRI studies which showed significant performance differences between patients and controls (ASD:4/12;OCD:4/14) did not differ between ASD and OCD ($\chi^2=0.07$,

p=0.8), suggesting that group-differences in performance did not contribute to activation differences.

Regional differences in GMV

ASD VBM analysis

ASD patients relative to controls showed reduced GMV in r/dACC/MPFC, right posterior insula and left cerebellum and enhanced GMV in left middle and superior temporal lobe (STL), right IPL/occipital lobe, left middle frontal gyrus (MFG), left and right precentral and right inferior temporal gyri (**Fig 1A;Table 3A**).

OCD VBM analysis

OCD patients relative to controls showed decreased GMV in v/r/dACC/MPFC, left VLPFC reaching into premotor cortex/insula/STL and in right IPL, left MFG/DLPFC and left VLPFC and increased GMV in bilateral putamen/caudate/nucleus accumbens (NAcc)/pallidum/amygdala/insula and in bilateral cerebellum, left postcentral gyrus and right superior parietal cortex (**Fig 1B;Table 3B**). Meta-regression revealed no association between GMV differences and anti-depressant use in patients at $p<.0005$.

Comparison of GMV differences between OCD and ASD

OCD compared to ASD patients (relative to respective control groups) showed larger GMV in bilateral putamen/caudate/NAcc/pallidum/amygdala/insula, extending into right STL, and in left caudate, right inferior temporal gyrus and cuneus but smaller GMV in dACC/MPFC, left superior frontal gyrus and right MFG/premotor cortex (**Fig 1C;Table 3C**). Effects in right inferior temporal gyrus, cuneus and right MFG/premotor cortex did not survive the age and sex-matched subgroup meta-analysis (**Supplementary Fig S1C;Table S1C**).

GMV conjunction/disjunction analysis

Shared GMV increases were in left ventral striatum (VS)/nucleus accumbens [MNI coord:-20,18,-10;voxels:390] and shared decreases in r/dACC/MPFC [MNI coord:4,44,26;voxels:1843]. Disjunction was seen in right putamen/caudate/insula [MNI coord:34,-4,4;voxels:874] where ASD had decreased GMV but OCD had increased GMV and in right IPL [MNI coord:52,-56,36;voxels:918], left STL [MNI coord:-44,12,-22;voxels:634] and left MFG [MNI coord:-20,32,42;voxels:458] where ASD had increased but OCD decreased GMV (**Fig 1D**). Effects in left VS/nucleus accumbens, right IPL, left STL and left MFG did not survive age and sex-matched subgroup meta-analysis (**Fig S1D**).

FMRI activation differences in inhibitory control tasks

ASD fMRI analysis

ASD patients relative to controls showed decreased activation in r/dACC/MPFC, left DLPFC, right VLPFC/anterior insula, left cerebellum vermis, left IPL and right MFG/premotor cortex. Enhanced activation relative to controls was in precuneus/posterior cingulate cortex (PCC), right inferior temporal/occipital and left middle temporal cortices (**Figure 1E;Table 4A**).

OCD fMRI analysis

OCD patients relative to controls showed decreased activation in v/r/dACC/MPFC, right caudate, right cerebellum, right STL/middle temporal gyrus, left postcentral gyrus and right PCC. Enhanced activation was observed in left insula/putamen/premotor cortex/ VLPFC/STL, right premotor cortex and left superior parietal cortex (**Figure 1F;Table 4B**). Meta-regression with medication status revealed no association between activation differences and anti-depressant use in patients at $p<.0005$.

Comparison of fMRI activation differences between OCD and ASD

Compared to ASD patients, OCD patients had increased activation in left MFG/DLPFC and left cerebellum but reduced activation in right STL/middle temporal lobe, left pre/post-central gyrus/IPL,

right and left PCC/precuneus, right and left VLPFC, right caudate, and right occipital lobe (**Fig 1G;Table 4C**). Effects in left cerebellum, right and left VLPFC, right occipital lobe, caudate and left PCC/precuneus did not survive age and sex-matched subgroup meta-analyses (**Supplement Fig S1G;Table S2C**). Confirmatory analyses including age as covariate confirmed results were not affected by non-significant age differences. Controlling for task-type, the majority of between-patient group-findings remained except disorder-specific underactivation in OCD patients in right STL/middle temporal lobe. Main findings remained when block-design studies which could be confounded by including error trials were excluded.

FMRI conjunction/disjunction analysis

Conjunction/disjunction analyses revealed shared underactivation in patient groups relative to controls in r/dACC/MPFC [MNI coord:0,32,34;voxels:3732]. Disjunction was seen in PCC/precuneus [MNI coord:-4,-34,46;voxels:393] where ASD showed increased but OCD decreased activation relative to controls and in left MFG/DLPFC [MNI coord:-36,32,24;voxels:101], where ASD showed decreased while OCD showed enhanced activation relative to controls (**Fig 1H**). The left MFG/DLPFC cluster did not survive age and sex-matched subgroup meta-analysis (**Fig S1H**).

Multimodal Analyses

Multimodal analyses in ASD

Multimodal analyses in ASD showed shared decreases in GMV and activation in dACC/MPFC [MNI coord:4,44,16;voxels:1802] and right insula [MNI coord:40,10,2;voxels:245]. The precuneus/PCC [MNI coord:4,-50,48;voxels:705] was decreased in GMV but increased in activation relative to controls (**Fig 1I**).

Multimodal analyses in OCD

Multimodal analyses in OCD showed shared GMV and activation reduction relative to controls in v/r/dACC/MPFC [MNI coord:6,36,46;voxels:5126] and shared increases in function and

structure in left anterior and posterior insula/putamen [MNI coord:-32,-8,-2;voxels:932] and right superior parietal gyrus [MNI coord:18,-54,72;voxels:137]. Left STL/precentral gyrus [MNI coord:-56,2,10;voxels:1524] was decreased in volume but increased in activation in patients relative to controls while right superior cerebellar hemisphere [MNI coord:28,-42,-16;voxels:1034], right anterior insula/putamen [MNI coord:18,0,-4;voxels:415] and right caudate [MNI coord:16,16,4;voxels:39] were increased in volume but decreased in activation (**Fig 1J**).

Multimodal comparison between ASD and OCD

Multimodal comparison between OCD and ASD (vs. controls) showed larger GMV and greater activation in left insula/putamen [MNI coord:-34,-6,4;voxels:822] were disorder-specific in OCD versus ASD patients. Enhanced GMV and decreased activation was disorder-specific in ASD relative to OCD in left STL [MNI coord:-58,-2,8;voxels:394] and right precentral gyrus/premotor cortex [MNI coord:44,8,44;voxels:180]. Disorder-specific decreased GMV but increased activation was seen in right amygdala/STL [MNI coord:24,2,-22;voxels:500] in ASD relative to OCD (**Fig 1K**). None of the regions that were disorder-specific to ASD survived age and sex-matched subgroup meta-analysis (**Fig S1K**).

Publication bias and robustness analysis

Egger's tests were non-significant (p>.05, Bonferroni corrected), suggesting there was no evidence of publication bias for the reported clusters. All disorder-specific and disorder-shared findings were robust **(Supplementary Tables S3-S10)**.

DISCUSSION

This first comparative multimodal meta-analysis of imaging studies of ASD and OCD shows both shared and disorder-specific abnormalities in brain structure and function during inhibitory control. Given group differences in age- and sex-distribution in the included studies, only findings that survived age and sex-matched subgroup meta-analyses are discussed.

Both disorders shared decreased volume and inhibitory activation in r/dACC/MPFC relative to controls. The most prominent disorder-specific finding was in left putamen and anterior and posterior insula where OCD patients had increased structure *and* inhibitory function compared to controls and ASD patients, while for the VBM meta-analysis, right putamen and insula which were increased in volume in OCD but decreased in ASD patients relative to controls.

Other disorder-differentiated structural abnormalities were in left superior frontal gyrus, which was reduced in volume in OCD patients relative to controls and ASD patients where it was enhanced relative to controls. For fMRI, disorder-specific effects were in left DLPFC, which was reduced, and PCC/precuneus, which was enhanced in function in ASD relative to OCD patients and controls. OCD patients had right superior temporal and inferior parietal underfunctioning relative to ASD patients and controls.

Rostral and dorsal ACC and MPFC are closely interconnected and together play a key role in top-down control of affect and motivation due to close connections with striato-limbic regions(60). While the vACC/MPFC is associated with affect control(61,62), more dorsal parts, in particular dACC, are crucial for inhibitory control(12,13,63,64) as well as for controlling affective VMPFC-limbic systems(65). The shared r/dACC/MPFC underactivation and reduced GMV may therefore reflect shared deficits in top-down inhibitory control over striato-limbic regions mediating motivation and affect. This finding extends previous meta-analyses in OCD patients showing GMV and inhibitory function in ACC/MPFC(18,36,37,47,60) relative to controls, as well as smaller structure/function in these regions in ASD patients(29,66), by showing that this multimodal MPFC dysfunction and dysmorphology is a shared phenotype which may reflect common problems with top-down cognitive and affect control which, furthermore, may be shared with a range of other affective disorders(60).

The disorder-specific finding of enhanced left striatal and insular function and structure in OCD relative to ASD patients together with reduced v/r/dACC/MPFC GMV and activation extends previous meta-analyses showing increased GMV in right insula(18) and left(18,36,37,47) and right BG

in OCD by showing that this is disorder-specific relative to ASD. They also extend fMRI studies showing dysfunction in dorsal-caudal putamen-mediated sensorimotor processing and inhibition(8) and posterior insula–mediated interoception and integration of sensory information in OCD(67). Thus, the findings extend current theories of fronto-striatal dysregulation in OCD, suggesting poor frontal lobe-mediated control over overactive striato-limbic activation in ventral and dorsal subregions of the BG, affecting motivation and affect as well as sensorimotor processing, respectively, ultimately resulting in poor control over obsessions, compulsions and anxiety by showing that this is disorder-specific to OCD. In ASD patients, by contrast, the shared reduced r/dACC/MPFC was concomitant with reduced structure in the right hemisphere homologue BG/insula regions relative to controls and OCD, suggesting a structural reduction in ASD of the entire r/d/MPFC/ACC-striato-limbic network as opposed to fronto-striatal dysregulation in OCD. Anterior insula and BG form part of inferior fronto-striatal inhibitory networks in children and adults(11,12,14,15) and are important for salience detection, motivation and habit-learning(12,68). In OCD, multimodal overlap of enhanced BG structure and function extends findings that enlarged BG volumes are related to poor inhibitory control(39) and that increased bottom-up influence of posterior insula and BG drives enhanced habit-based responses and altered interoceptive processing at the expense of externally-motivated goal-directed actions such as inhibitory control(69). There is also evidence in OCD of enhanced striatal synaptic dopamine, which may be related to hyperactivation and enhanced volumes(70). In ASD, anterior insula underactivation has been linked to abnormalities in saliency processing(29). Thus, disorder-specific findings of enhanced insula/BG function and structure in OCD relative to ASD patients and controls, but reduced right insula/BG volume in ASD relative to controls are in line with predominant theories of fronto-striatal dysregulation in OCD involving reduced ventromedial prefrontal control over enhanced striato-insular structure and function linked to interoceptive abnormalities(69) and with evidence for overall reduced function and structure in these regions in ASD(71), suggesting abnormalities in the saliency network. Importantly, the findings suggest that a shared neurocognitive phenotype of poor top-

down inhibitory control over behaviour and affect is underpinned by differing underlying structural and functional fronto-striato-insular networks in the two disorders.

Disorder-differentiated structural abnormalities were also observed in left superior frontal gyrus, which was decreased in GMV in OCD versus ASD patients and controls but increased in GMV in ASD versus controls. This extends a previous VBM meta-analysis(72) by showing that superior frontal GMV reduction is disorder-specific relative to ASD patients, who typically have enhanced dorsal and superior frontal volumes(73), which furthermore correlated with ASD symptom severity(74). Enhanced frontal volumes in ASD also extends evidence of early frontal grey matter overgrowth which appears arrested later in life(73).

In fMRI, left DLPFC activation was disorder-specifically reduced in ASD patients relative to controls and OCD patients. Left DLPFC is involved in goal representation and attention selection as well as response inhibition and maintenance of stimulus representations in the presence of distracting or interfering events(75). DLPFC hypoactivation has been observed in ASD during cognitive control tasks involving inhibition(26), attention(76,77) and working-memory(29,78). We previously found that left DLPFC hypoactivation in ASD is associated and anti-correlated with increased PCC activation during sustained attention(76), which was also enhanced in this meta-analysis in ASD relative to controls and OCD. PCC is a key node in the default mode network (DMN) thought to reflect task-irrelevant thinking and typically less deactivated during cognitive tasks in ASD(79), including attention(80) and interference inhibition(81), presumably reflecting increased mind wandering. Here, we show that decreased left DLPFC activation together with reduced deactivation of DMN regions including PCC is disorder-specific to ASD and may be related to attention problems typically observed in the disorder(76), although DMN abnormalities have also been observed in OCD(82,83).

OCD patients showed disorder-specific decreased inhibitory activation relative to ASD patients and controls in right STL and left IPL, extending findings of temporo-parietal underactivation

during interference inhibition(55,56,84), response inhibition(85), planning(86), and switching(82). Superior temporal and IPL regions presumably are involved during inhibition tasks due to their function in visual-spatial attention to salient stimuli(16,87). It has been argued that while there is enhanced salience processing of disorder-relevant and symptom-triggering stimuli in OCD (e.g. contamination for compulsive washers), there is reduced visual-spatial saliency processing in posterior visual-spatial attention regions during cognitive tasks, presumably due to the over-recruitment of these regions in relation to symptom-related saliency(16,82), which likely underlies poor performance on selective attention and inhibitory control tasks(88). The findings suggest disorder-dissociated reduced recruitment of DLPFC in ASD and temporo-parietal regions in OCD during inhibitory control, presumably underlying their respective attention problems.

This study has several limitations. This study was based primarily on peak coordinates, as statistical brain maps were difficult to obtain. Studies used different statistical thresholds, so that weak group differences may be lost from studies using conservative thresholds which may have led to decreased statistical power. This is however counterbalanced by the large number of included studies. We also acknowledge that, as whole-brain analyses may be underpowered to detect differences within specific ROIs, our meta-analysis cannot discount the absence of other findings reported in ROI-based studies, such as ACC hyperactivation/failure of deactivation that has previously been observed in OCD patients compared to controls during tasks of cognitive control (e.g. (89-91). ASD studies included younger and more male patients. However, this was controlled for by covariance analyses and sex and age-matched subgroup meta-analyses. Areas that did not survive these subgroup analyses were not discussed. Additionally, although inclusion criteria tried to rule out the possibility of comorbidity between OCD and ASD, it is possible that some OCD studies did not screen for ASD comorbidity or that ASD studies conflated OCD symptoms with the broader ASD phenotype. This might have reduced the disorder-specific findings. The combination of different fMRI tasks within the same inhibitory control domain presents some variability. However, findings survived when task-type was covaried. Moreover, common fronto-striato-parietal activation

patterns underlie these different inhibitory control tasks(11). Furthermore, given evidence for developmental differences in brain structure in both OCD(38) and ASD(92), it would have been interesting to conduct sub-meta-analyses of pediatric and adult subsamples. For example, a recent mega-analysis in OCD found that GMV in putamen, insula and OFC declined with increasing age in controls but not OCD patients(38). However, due to the small number of pediatric studies, particularly in the fMRI sample (e.g. 4 OCD studies), results would have been underpowered. Nonetheless, developmental factors should be considered in future meta-analyses once more pediatric studies are available.

Conclusions

This comparative multimodal meta-analysis shows that different fronto-striato-insular abnormalities underlie seemingly similar behavioural phenotypes in ASD and OCD. They share functional and structural abnormalities in r/dACC/MPFC. However, they differ in functional and structural abnormalities in BG/insula which were increased in OCD, in line with medial fronto-striatal dysregulation models of poor top-down frontal control over hyperactive striato-limbic regions while in ASD, they were decreased, suggesting reduced function and structure in medial fronto-striato-limbic networks.

Acknowledgements

CC is supported by a National Institute for Health Research (NIHR) Biomedical Research Centre PhD studentship and a King's College London overseas graduate award. LN and SL are supported by Medical Research Council (MRC) and Institute of Psychiatry, Psychology and Neuroscience Ph.D. Excellence awards.

We would like to thank Toby Wise for his insightful discussions on the statistical methods used in this meta-analysis. We also thank all authors of included studies who provided additional study details, co-ordinates and t-maps for their co-operation.

Disclosures

KR has received speaker's honoraria from Lilly and Shire and received a grant from Lilly for another project. The other authors report no biomedical financial interests or potential conflicts of interest.

References

1. APA (2013): Diagnostic and statistical manual of mental disorders. 5th ed. Arlington, VA: American Psychiatric Publishing.

2. Baird G, Simonoff E, Pickles A, Chandler S, Loucas T, Meldrum D, et al. (2006): Prevalence of disorders of the autism spectrum in a population cohort of children in South Thames: the Special Needs and Autism Project (SNAP). The Lancet. 368:210-215.

3. Ruscio A, Stein D, Chiu W, Kessler R (2010): The epidemiology of obsessive-compulsive disorder in the National Comorbidity Survey Replication. Molecular Psychiatry. 15:53-63.

4. Wiggins LD, Robins DL, Adamson LB, Bakeman R, Henrich CC (2012): Support for a Dimensional View of Autism Spectrum Disorders in Toddlers. J Autism Dev Disord. 42:191-200.

5. Russell AJ, Mataix-Cols D, Anson M, Murphy DGM (2005): Obsessions and compulsions in Asperger syndrome and high-functioning autism. The British Journal of Psychiatry. 186:525-528.

6. Robbins TW, Gillan CM, Smith DG, de Wit S, Ersche KD (2012): Neurocognitive endophenotypes of impulsivity and compulsivity: towards dimensional psychiatry. Trends in Cognitive Sciences. 16:81-91.

7. Geurts HM, van den Bergh SFWM, Ruzzano L (2014): Prepotent Response Inhibition and Interference Control in Autism Spectrum Disorders: Two Meta-Analyses. Autism Research. 7:407-420.

8. van Velzen LS, Vriend C, de Wit SJ, van den Heuvel OA (2014): Response inhibition and interference control in obsessive-compulsive spectrum disorders. Frontiers in Human Neuroscience. 8.

9. Aron AR (2011): From reactive to proactive and selective control: developing a richer model for stopping inappropriate responses. Biological Psychiatry. 69:e55-e68.

10. Rubia K, Smith A, Taylor E (2007): Performance of Children with Attention Deficit Hyperactivity Disorder (ADHD) on a Test Battery of Impulsiveness. Child Neuropsychology. 13:276 - 304.

11. Hugdahl K, Raichle ME, Mitra A, Specht K (2015): On the existence of a generalized non-specific task-dependent network. Frontiers in Human Neuroscience. 9.

12. Cai W, Ryali S, Chen T, Li C-SR, Menon V (2014): Dissociable Roles of Right Inferior Frontal Cortex and Anterior Insula in Inhibitory Control: Evidence from Intrinsic and Task-Related Functional Parcellation, Connectivity, and Response Profile Analyses across Multiple Datasets. The Journal of Neuroscience. 34:14652-14667.

13. Rae CL, Hughes LE, Weaver C, Anderson MC, Rowe JB (2014): Selection and stopping in voluntary action: A meta-analysis and combined fMRI study. NeuroImage. 86:381-391.

14. Rubia K, Lim L, Ecker C, Halari R, Giampietro V, Simmons A, et al. (2013): Effects of age and gender on neural networks of motor response inhibition: From adolescence to mid-adulthood. NeuroImage. 83:690-703.

15. Dambacher F, Sack AT, Lobbestael J, Arntz A, Brugman S, Schuhmann T (2014): A network approach to response inhibition: dissociating functional connectivity of neural components involved in action restraint and action cancellation. European Journal of Neuroscience. 39:821-831.

16. Rubia K, Cubillo A, Woolley J, Brammer MJ, Smith A (2011): Disorder-specific dysfunctions in patients with attention-deficit/hyperactivity disorder compared to patients with obsessive-compulsive disorder during interference inhibition and attention allocation. Human Brain Mapping. 32:601-611.

17. Dickstein DP, Pescosolido MF, Reidy BL, Galvan T, Kim KL, Seymour KE, et al. (2013): Developmental Meta-Analysis of the Functional Neural Correlates of Autism Spectrum Disorders. Journal of the American Academy of Child & Adolescent Psychiatry. 52:279-289.

18. Eng GK, Sim K, Chen S-HA (2015): Meta-analytic investigations of structural grey matter, executive domain-related functional activations, and white matter diffusivity in obsessive compulsive disorder: An integrative review. Neuroscience & Biobehavioral Reviews. 52:233-257.

19. Chantiluke K, Barrett N, Giampietro V, Santosh P, Brammer M, Simmons A, et al. (2015): Inverse fluoxetine effects on inhibitory brain activation in non-comorbid boys with ADHD and with ASD. Psychopharmacology. 232:2071-2082.

20. Chmielewski WX, Beste C (2015): Action control processes in autism spectrum disorder – Insights from a neurobiological and neuroanatomical perspective. Progress in Neurobiology. 124:49-83.

21. Duerden EG, Taylor MJ, Soorya LV, Wang T, Fan J, Anagnostou E (2013): Neural correlates of inhibition of socially relevant stimuli in adults with autism spectrum disorder. Brain Research. 1533:80-90.

22. Daly E, Ecker C, Hallahan B, Deeley Q, Craig M, Murphy C, et al. (2014): Response inhibition and serotonin in autism: a functional MRI study using acute tryptophan depletion. Brain. 137:2600-2610.

23. Shafritz KM, Bregman JD, Ikuta T, Szeszko PR (2015): Neural systems mediating decision-making and response inhibition for social and nonsocial stimuli in autism. Progress in Neuro-Psychopharmacology and Biological Psychiatry. 60:112-120.

24. Vaidya CJ, Foss-Feig J, Shook D, Kaplan L, Kenworthy L, Gaillard WD (2011): Controlling attention to gaze and arrows in childhood: an fMRI study of typical development and Autism Spectrum Disorders. Developmental Science. 14:911-924.

25. Fan J, Bernardi S, Van Dam NT, Anagnostou E, Gu X, Martin L, et al. (2012): Functional deficits of the attentional networks in autism. Brain and Behavior. 2:647-660.

26. Kana RK, Keller TA, Minshew NJ, Just MA (2007): Inhibitory Control in High-Functioning Autism: Decreased Activation and Underconnectivity in Inhibition Networks. Biological Psychiatry. 62:198-206.

27. Schmitz N, Rubia K, Daly E, Smith A, Williams S, Murphy DGM (2006): Neural Correlates of Executive Function in Autistic Spectrum Disorders. Biological Psychiatry. 59:7-16.

28. Solomon M, Yoon JH, Ragland JD, Niendam TA, Lesh TA, Fairbrother W, et al. (2014): The Development of the Neural Substrates of Cognitive Control in Adolescents with Autism Spectrum Disorders. Biological Psychiatry. 76:412-421.

29. Di Martino A, Ross K, Uddin LQ, Sklar AB, Castellanos FX, Milham MP (2009): Functional Brain Correlates of Social and Nonsocial Processes in Autism Spectrum Disorders: An Activation Likelihood Estimation Meta-Analysis. Biological Psychiatry. 65:63-74.

30. Philip RCM, Dauvermann MR, Whalley HC, Baynham K, Lawrie SM, Stanfield AC (2012): A systematic review and meta-analysis of the fMRI investigation of autism spectrum disorders. Neuroscience & Biobehavioral Reviews. 36:901-942.

31. Via E, Radua J, Cardoner N, Happé F, Mataix-Cols D (2011): Meta-analysis of gray matter abnormalities in autism spectrum disorder: Should asperger disorder be subsumed under a broader umbrella of autistic spectrum disorder? Archives of General Psychiatry. 68:409-418.

32. DeRamus TP, Kana RK (2015): Anatomical likelihood estimation meta-analysis of grey and white matter anomalies in autism spectrum disorders. NeuroImage: Clinical. 7:525-536.

33. Nickl-Jockschat T, Habel U, Maria Michel T, Manning J, Laird AR, Fox PT, et al. (2012): Brain structure anomalies in autism spectrum disorder—a meta-analysis of VBM studies using anatomic likelihood estimation. Human Brain Mapping. 33:1470-1489.

34. Wolff JJ, Hazlett HC, Lightbody AA, Reiss AL, Piven J (2013): Repetitive and self-injurious behaviors: associations with caudate volume in autism and fragile X syndrome. Journal of Neurodevelopmental Disorders. 5:12.

35. Rubia K, Cubillo A, Smith AB, Woolley J, Heyman I, Brammer MJ (2010): Disorder-specific dysfunction in right inferior prefrontal cortex during two inhibition tasks in boys with attention-deficit hyperactivity disorder compared to boys with obsessive–compulsive disorder. Human Brain Mapping. 31:287-299.

36. Radua J, van den Heuvel OA, Surguladze S, Mataix-Cols D (2010): Meta-analytical comparison of voxel-based morphometry studies in obsessive-compulsive disorder vs other anxiety disorders. Archives of General Psychiatry. 67:701-711.

37. Peng Z, Lui SSY, Cheung EFC, Jin Z, Miao G, Jing J, et al. (2012): Brain structural abnormalities in obsessive-compulsive disorder: Converging evidence from white matter and grey matter. Asian Journal of Psychiatry. 5:290-296.

38. deWit SJ, Alonso P, Schweren L, Mataix-Cols D, Lochner C, Menchón JM, et al. (2014): Multicenter Voxel-Based Morphometry Mega-Analysis of Structural Brain Scans in Obsessive-Compulsive Disorder. American Journal of Psychiatry. 171:340-349.

39. Menzies L, Achard S, Chamberlain SR, Fineberg N, Chen C-H, del Campo N, et al. (2007): Neurocognitive endophenotypes of obsessive-compulsive disorder. Brain. 130:3223-3236.

40. Hart H, Radua J, Mataix-Cols D, Rubia K (2012): Meta-analysis of fMRI studies of timing in attention-deficit hyperactivity disorder (ADHD). Neuroscience & Biobehavioral Reviews. 36:2248-2256.

41. Hart H, Radua J, Nakao T, Mataix-Cols D, Rubia K (2013): Meta-analysis of functional magnetic resonance imaging studies of inhibition and attention in attention-deficit/hyperactivity disorder: Exploring task-specific, stimulant medication, and age effects. JAMA Psychiatry. 70:185-198.

42. Norman LJ, Carlisi C, Lukito S, Hart H, Mataix-Cols D, Radua J, et al. (2016): Structural and functional brain abnormalities in attention-deficit/hyperactivity disorder and obsessive-compulsive disorder: A comparative meta-analysis. JAMA Psychiatry.

43. Nakao T, Radua J, Rubia K, Mataix-Cols D (2011): Gray matter volume abnormalities in ADHD: voxel-based meta-analysis exploring the effects of age and stimulant medication. American Journal of Psychiatry. 168:1154-1163.

44. Rubia K, Alegria AA, Cubillo AI, Smith AB, Brammer MJ, Radua J (2014): Effects of Stimulants on Brain Function in Attention-Deficit/Hyperactivity Disorder: A Systematic Review and Meta-Analysis. Biological Psychiatry. 76:616-628.

45. Lim L, Radua J, Rubia K (2014): Gray matter abnormalities in childhood maltreatment: a voxel-wise meta-analysis. American Journal of Psychiatry.

46. Radua J, Grau M, van den Heuvel OA, Thiebaut de Schotten M, Stein DJ, Canales-Rodriguez EJ, et al. (2014): Multimodal Voxel-Based Meta-Analysis of White Matter Abnormalities in Obsessive-Compulsive Disorder. Neuropsychopharmacology. 39:1547-1557.

47. Radua J, Mataix-Cols D (2009): Voxel-wise meta-analysis of grey matter changes in obsessive–compulsive disorder. The British Journal of Psychiatry. 195:393-402.

48. Radua J, Pozo NOd, Gómez J, Guillen-Grima F, Ortuño F (2014): Meta-analysis of functional neuroimaging studies indicates that an increase of cognitive difficulty during executive tasks engages brain regions associated with time perception. Neuropsychologia. 58:14-22.

49. Ersche KD, Williams GB, Robbins TW, Bullmore ET (2013): Meta-analysis of structural brain abnormalities associated with stimulant drug dependence and neuroimaging of addiction vulnerability and resilience. Current opinion in neurobiology. 23:615-624.

50. Gabay AS, Radua J, Kempton MJ, Mehta MA (2014): The Ultimatum Game and the brain: A meta-analysis of neuroimaging studies. Neuroscience & Biobehavioral Reviews. 47:549-558.

51. Stroup DF, Berlin JA, Morton SC, et al. (2000): Meta-analysis of observational studies in epidemiology: A proposal for reporting. Journal of the American Medical Association. 283:2008-2012.

52. Radua J, Rubia K, Canales-Rodríguez EJ, Pomarol-Clotet E, Fusar-Poli P, Mataix-Cols D (2014): Anisotropic kernels for coordinate-based meta-analyses of neuroimaging studies. Frontiers in Psychiatry. 5.

53. Radua J, Mataix-Cols D, Phillips ML, El-Hage W, Kronhaus DM, Cardoner N, et al. (2012): A new meta-analytic method for neuroimaging studies that combines reported peak coordinates and statistical parametric maps. European Psychiatry. 27:605-611.

54. Morein-Zamir S, Voon V, Dodds CM, Sule A, van Niekerk J, Sahakian BJ, et al. (2015): Divergent subcortical activity for distinct executive functions: stopping and shifting in obsessive compulsive disorder. Psychological Medicine. FirstView:1-12.

55. Woolley J, Heyman I, Brammer M, Frampton I, McGuire PK, Rubia K (2008): Brain activation in paediatric obsessive–compulsive disorder during tasks of inhibitory control. The British Journal of Psychiatry. 192:25-31.

56. Page LA, Rubia K, Deeley Q, Daly E, Toal F, Mataix-Cols D, et al. (2009): A functional magnetic resonance imaging study of inhibitory control in obsessive-compulsive disorder. Psychiatry Research: Neuroimaging. 174:202-209.

57. Hashimoto N, Nakaaki S, Kawaguchi A, Sato J, Kasai H, Nakamae T, et al. (2014): Brain structural abnormalities in behavior therapy-resistant obsessive-compulsive disorder revealed by voxel-based morphometry. Neuropsychiatric Disease and Treatment. 10:1987-1996.

58. Subirà M, Alonso P, Segalàs C, Real E, López-Solà C, Pujol J, et al. (2013): Brain Structural Alterations in Obsessive-Compulsive Disorder Patients with Autogenous and Reactive Obsessions. PLoS One. 8:e75273.

59. Radua J, Romeo M, Mataix-Cols D, Fusar-Poli P (2013): A general approach for combining voxel-based meta-analyses conducted in different neuroimaging modalities. Current Medicinal Chemistry. 20:462-466.

60. Goodkind M, Eickhoff SB, Oathes DJ, et al. (2015): Identification of a common neurobiological substrate for mental illness. JAMA Psychiatry. 72:305-315.

61. Buhle JT, Silvers JA, Wager TD, Lopez R, Onyemekwu C, Kober H, et al. (2014): Cognitive reappraisal of emotion: a meta-analysis of human neuroimaging studies. Cerebral Cortex. 24:2981-2990.

62. Shenhav A, Botvinick MM, Cohen JD (2013): The expected value of control: an integrative theory of anterior cingulate cortex function. Neuron. 79:217-240.

63. Levy BJ, Wagner AD (2011): Cognitive control and right ventrolateral prefrontal cortex: reflexive reorienting, motor inhibition, and action updating. Annals of the New York Academy of Sciences. 1224:40-62.

64. Swick D, Ashley V, Turken U (2011): Are the neural correlates of stopping and not going identical? Quantitative meta-analysis of two response inhibition tasks. NeuroImage. 56:1655-1665.

65. Etkin A, Egner T, Kalisch R (2011): Emotional processing in anterior cingulate and medial prefrontal cortex. Trends in Cognitive Sciences. 15:85-93.

66. Ha S, Sohn I-J, Kim N, Sim HJ, Cheon K-A (2015): Characteristics of Brains in Autism Spectrum Disorder: Structure, Function and Connectivity across the Lifespan. Experimental Neurobiology 24:273-284.

67. Nagai M, Kishi K, Kato S (2007): Insular cortex and neuropsychiatric disorders: A review of recent literature. European Psychiatry. 22:387-394.

68. Gillan CM, Robbins TW (2014): Goal-directed learning and obsessive–compulsive disorder. Philosophical Transactions of the Royal Society of London B: Biological Sciences. 369.

69. Fineberg NA, Chamberlain SR, Goudriaan AE, Stein DJ, Vanderschuren LJMJ, Gillan CM, et al. (2014): New developments in human neurocognition: clinical, genetic, and brain imaging correlates of impulsivity and compulsivity. CNS Spectrums. 19:69-89.

70. Nikolaus S, Antke C, Beu M, Müller H-W (2010): Cortical GABA, striatal dopamine and midbrain serotonin as the key players in compulsive and anxiety disorders-results from in vivo imaging studies. Reviews in the Neurosciences. 21:119-140.

71. Uddin LQ, Menon V (2009): The anterior insula in autism: under-connected and under-examined. Neuroscience & Biobehavioral Reviews. 33:1198-1203.

72. Rotge J-Y, Langbour N, Guehl D, Bioulac B, Jaafari N, Allard M, et al. (2010): Gray matter alterations in obsessive–compulsive disorder: an anatomic likelihood estimation meta-analysis. Neuropsychopharmacology. 35:686-691.

73. Courchesne E, Pierce K, Schumann CM, Redcay E, Buckwalter JA, Kennedy DP, et al. (2007): Mapping Early Brain Development in Autism. Neuron. 56:399-413.

74. Rojas DC, Peterson E, Winterrowd E, Reite ML, Rogers SJ, Tregellas JR (2006): Regional gray matter volumetric changes in autism associated with social and repetitive behavior symptoms. BMC Psychiatry. 6:56.

75. Ridderinkhof KR, van den Wildenberg WPM, Segalowitz SJ, Carter CS (2004): Neurocognitive mechanisms of cognitive control: The role of prefrontal cortex in action selection, response inhibition, performance monitoring, and reward-based learning. Brain and Cognition. 56:129-140.

76. Christakou A, Murphy C, Chantiluke K, Cubillo A, Smith A, Giampietro V, et al. (2013): Disorder-specific functional abnormalities during sustained attention in youth with Attention Deficit Hyperactivity Disorder (ADHD) and with Autism. Molecular Psychiatry. 18:236-244.

77. Silk T, Rinehart N, Bradshaw J, Tonge B, Egan G, O'Boyle M, et al. (2006): Visuospatial processing and the function of prefrontal-parietal networks in autism spectrum disorders: a functional MRI study. American Journal of Psychiatry. 163:1440-1443.

78. Stigler KA, McDonald BC, Anand A, Saykin AJ, McDougle CJ (2011): Structural and functional magnetic resonance imaging of autism spectrum disorders. Brain Research. 1380:146-161.

79. Minshew NJ, Keller TA (2010): The nature of brain dysfunction in autism: functional brain imaging studies. Current Opinion in Neurology. 23:124.

80. Gadgil M, Peterson E, Tregellas J, Hepburn S, Rojas DC (2013): Differences in global and local level information processing in autism: An fMRI investigation. Psychiatry Research: Neuroimaging. 213:115-121.

81. Kennedy DP, Redcay E, Courchesne E (2006): Failing to deactivate: resting functional abnormalities in autism. Proceedings of the National Academy of Sciences. 103:8275-8280.

82. Menzies L, Chamberlain SR, Laird AR, Thelen SM, Sahakian BJ, Bullmore ET (2008): Integrating evidence from neuroimaging and neuropsychological studies of obsessive-compulsive disorder: The orbitofronto-striatal model revisited. Neuroscience & Biobehavioral Reviews. 32:525-549.

83. Stern ER, Taylor SF (2014): Cognitive Neuroscience of Obsessive-Compulsive Disorder. Psychiatric Clinics of North America. 37:337-352.

84. Nakao T, Nakagawa A, Yoshiura T, Nakatani E, Nabeyama M, Yoshizato C, et al. (2005): A functional MRI comparison of patients with obsessive–compulsive disorder and normal controls during a Chinese character Stroop task. Psychiatry Research: Neuroimaging. 139:101-114.

85. Roth RM, Saykin AJ, Flashman LA, Pixley HS, West JD, Mamourian AC (2007): Event-related functional magnetic resonance imaging of response inhibition in obsessive-compulsive disorder. Biological Psychiatry. 62:901-909.

86. van den Heuvel OA, Veltman DJ, Groenewegen HJ, et al. (2005): Frontal-striatal dysfunction during planning in obsessive-compulsive disorder. Archives of General Psychiatry. 62:301-309.

87. Rubia K, Smith AB, Woolley J, Nosarti C, Heyman I, Taylor E, et al. (2006): Progressive increase of frontostriatal brain activation from childhood to adulthood during event-related tasks of cognitive control. Human Brain Mapping. 27:973-993.

88. Chamberlain S, Blackwell A, Fineberg NA, Robbins T, Sahakian B (2005): The neuropsychology of obsessive compulsive disorder: the importance of failures in cognitive and behavioural inhibition as candidate endophenotypic markers. Neuroscience & Biobehavioral Reviews. 29:399-419.

89. Ursu S, Stenger VA, Shear MK, Jones MR, Carter CS (2003): Overactive Action Monitoring in Obsessive-Compulsive Disorder: Evidence From Functional Magnetic Resonance Imaging. Psychological Science. 14:347-353.

90. Maltby N, Tolin DF, Worhunsky P, O'Keefe TM, Kiehl KA (2005): Dysfunctional action monitoring hyperactivates frontal–striatal circuits in obsessive–compulsive disorder: an event-related fMRI study. Neuroimage. 24:495-503.

91. Fitzgerald KD, Stern ER, Angstadt M, Nicholson-Muth KC, Maynor MR, Welsh RC, et al. (2010): Altered Function and Connectivity of the Medial Frontal Cortex in Pediatric Obsessive-Compulsive Disorder. Biological Psychiatry. 68:1039-1047.

92. Courchesne E, Campbell K, Solso S (2011): Brain growth across the life span in autism: Age-specific changes in anatomical pathology. Brain Research. 1380:138-145.

93. Abell F, Krams M, Ashburner J, Passingham R, Friston K, Frackowiak R, et al. (1999): The neuroanatomy of autism: a voxel - based whole brain analysis of structural scans. Neuroreport. 10:1647-1651.

94. McAlonan GM, Daly E, Kumari V, Critchley HD, van Amelsvoort T, Suckling J, et al. (2002): Brain anatomy and sensorimotor gating in Asperger's syndrome. Brain. 125:1594-1606.

95. Boddaert N, Chabane N, Gervais H, Good C, Bourgeois M, Plumet M, et al. (2004): Superior temporal sulcus anatomical abnormalities in childhood autism: a voxel-based morphometry MRI study. Neuroimage. 23:364-369.

96. Waiter GD, Williams JH, Murray AD, Gilchrist A, Perrett DI, Whiten A (2004): A voxel-based investigation of brain structure in male adolescents with autistic spectrum disorder. Neuroimage. 22:619-625.

97. Kwon H, Ow AW, Pedatella KE, Lotspeich LJ, Reiss AL (2004): Voxel-based morphometry elucidates structural neuroanatomy of high-functioning autism and Asperger syndrome. Developmental Medicine & Child Neurology. 46:760-764.

98. Brieber S, Neufang S, Bruning N, Kamp - Becker I, Remschmidt H, Herpertz - Dahlmann B, et al. (2007): Structural brain abnormalities in adolescents with autism spectrum disorder and patients with attention deficit/hyperactivity disorder. Journal of Child Psychology and Psychiatry. 48:1251-1258.

99. Craig MC, Zaman SH, Daly EM, Cutter WJ, Robertson DM, Hallahan B, et al. (2007): Women with autistic-spectrum disorder: magnetic resonance imaging study of brain anatomy. The British Journal of Psychiatry. 191:224-228.

100. Bonilha L, Cendes F, Rorden C, Eckert M, Dalgalarrondo P, Li LM, et al. (2008): Gray and white matter imbalance – Typical structural abnormality underlying classic autism? Brain and Development. 30:396-401.

101. Freitag CM, Konrad C, Häberlen M, Kleser C, von Gontard A, Reith W, et al. (2008): Perception of biological motion in autism spectrum disorders. Neuropsychologia. 46:1480-1494.

102. Ke X, Hong S, Tang T, Zou B, Li H, Hang Y, et al. (2008): Voxel-based morphometry study on brain structure in children with high-functioning autism. Neuroreport. 19:921-925.

103. McAlonan GM, Suckling J, Wong N, Cheung V, Lienenkaemper N, Cheung C, et al. (2008): Distinct patterns of grey matter abnormality in high-functioning autism and Asperger's syndrome. Journal of Child Psychology and Psychiatry. 49:1287-1295.

104. Langen M, Schnack HG, Nederveen H, Bos D, Lahuis BE, de Jonge MV, et al. (2009): Changes in the developmental trajectories of striatum in autism. Biological Psychiatry. 66:327-333.

105. Wilson LB, Tregellas JR, Hagerman RJ, Rogers SJ, Rojas DC (2009): A voxel-based morphometry comparison of regional gray matter between fragile X syndrome and autism. Psychiatry Research: Neuroimaging. 174:138-145.

106. Toal F, Daly E, Page L, Deeley Q, Hallahan B, Bloemen O, et al. (2010): Clinical and anatomical heterogeneity in autistic spectrum disorder: a structural MRI study. Psychological Medicine. 40:1171-1181.

107. Hyde KL, Samson F, Evans AC, Mottron L (2010): Neuroanatomical differences in brain areas implicated in perceptual and other core features of autism revealed by cortical thickness analysis and voxel-based morphometry. Human Brain Mapping. 31:556-566.

108. Kosaka H, Omori M, Munesue T, Ishitobi M, Matsumura Y, Takahashi T, et al. (2010): Smaller insula and inferior frontal volumes in young adults with pervasive developmental disorders. Neuroimage. 50:1357-1363.

109. Mengotti P, D'Agostini S, Terlevic R, De Colle C, Biasizzo E, Londero D, et al. (2011): Altered white matter integrity and development in children with autism: A combined voxel-based morphometry and diffusion imaging study. Brain Research Bulletin. 84:189-195.

110. Riva D, Bulgheroni S, Aquino D, Di Salle F, Savoiardo M, Erbetta A (2011): Basal forebrain involvement in low-functioning autistic children: a voxel-based morphometry study. American Journal of Neuroradiology. 32:1430-1435.

111. Groen WB, Buitelaar JK, Van Der Gaag RJ, Zwiers MP (2011): Pervasive microstructural abnormalities in autism: a DTI study. Journal of Psychiatry & Neuroscience: JPN. 36:32.

112. Kurth F, Narr KL, Woods RP, O'Neill J, Alger JR, Caplan R, et al. (2011): Diminished Gray Matter Within the Hypothalamus in Autism Disorder: A Potential Link to Hormonal Effects? Biological Psychiatry. 70:278-282.

113. Poustka L, Jennen-Steinmetz C, Henze R, Vomstein K, Haffner J, Sieltjes B (2012): Fronto-temporal disconnectivity and symptom severity in children with autism spectrum disorder. The World Journal of Biological Psychiatry. 13:269-280.

114. Calderoni S, Retico A, Biagi L, Tancredi R, Muratori F, Tosetti M (2012): Female children with autism spectrum disorder: an insight from mass-univariate and pattern classification analyses. Neuroimage. 59:1013-1022.

115. Ecker C, Suckling J, Deoni SC, Lombardo MV, Bullmore ET, Baron-Cohen S, et al. (2012): Brain anatomy and its relationship to behavior in adults with autism spectrum disorder: a multicenter magnetic resonance imaging study. Archives of General Psychiatry. 69:195-209.

116. Greimel E, Nehrkorn B, Schulte-Rüther M, Fink GR, Nickl-Jockschat T, Herpertz-Dahlmann B, et al. (2013): Changes in grey matter development in autism spectrum disorder. Brain Structure and Function. 218:929-942.

117. Mueller S, Keeser D, Samson AC, Kirsch V, Blautzik J, Grothe M, et al. (2013): Convergent findings of altered functional and structural brain connectivity in individuals with high functioning autism: a multimodal MRI study. PLoS One. 8:e67329.

118. Poulin-Lord M-P, Barbeau EB, Soulières I, Monchi O, Doyon J, Benali H, et al. (2014): Increased topographical variability of task-related activation in perceptive and motor associative regions in adult autistics. Neuroimage: Clinical. 4:444-453.

119. Lim L, Chantiluke K, Cubillo AI, Smith AB, Simmons A, Mehta MA, et al. (2015): Disorder-specific grey matter deficits in attention deficit hyperactivity disorder relative to autism spectrum disorder. Psychological Medicine. 45:965-976.

120. Gori I, Giuliano A, Muratori F, Saviozzi I, Oliva P, Tancredi R, et al. (2015): Gray Matter Alterations in Young Children with Autism Spectrum Disorders: Comparing Morphometry at the Voxel and Regional Level. Journal of Neuroimaging. 25:866-874.

121. Itahashi T, Yamada T, Nakamura M, Watanabe H, Yamagata B, Jimbo D, et al. (2015): Linked alterations in gray and white matter morphology in adults with high-functioning autism spectrum disorder: A multimodal brain imaging study. NeuroImage: Clinical. 7:155-169.

122. Foster NEV, Doyle-Thomas KAR, Tryfon A, Ouimet T, Anagnostou E, Evans AC, et al. (2015): Structural Gray Matter Differences During Childhood Development in Autism Spectrum Disorder: A Multimetric Approach. Pediatric Neurology. 53:350-359.

123. Pujol J, Soriano-Mas C, Alonso P, Cardoner N, Menchón JM, Deus J, et al. (2004): Mapping structural brain alterations in obsessive-compulsive disorder. Archives of General Psychiatry. 61:720-730.

124. Riffkin J, Yücel M, Maruff P, Wood SJ, Soulsby B, Olver J, et al. (2005): A manual and automated MRI study of anterior cingulate and orbito-frontal cortices, and caudate nucleus in obsessive-compulsive disorder: comparison with healthy controls and patients with schizophrenia. Psychiatry Research: Neuroimaging. 138:99-113.

125. Valente Jr AA, Miguel EC, Castro CC, Amaro Jr E, Duran FLS, Buchpiguel CA, et al. (2005): Regional Gray Matter Abnormalities in Obsessive-Compulsive Disorder: A Voxel-Based Morphometry Study. Biological Psychiatry. 58:479-487.

126. Carmona S, Bassas N, Rovira M, Gispert J-D, Soliva J-C, Prado M, et al. (2007): Pediatric OCD structural brain deficits in conflict monitoring circuits: A voxel-based morphometry study. Neuroscience Letters. 421:218-223.

127. Soriano-Mas C, Pujol J, Alonso P, Cardoner N, Menchón JM, Harrison BJ, et al. (2007): Identifying patients with obsessive–compulsive disorder using whole-brain anatomy. Neuroimage. 35:1028-1037.

128. Yoo SY, Roh M-S, Choi J-S, Kang D-H, Ha TH, Lee J-M, et al. (2008): Voxel-based morphometry study of gray matter abnormalities in obsessive-compulsive disorder. Journal of Korean Medical Science. 23:24-30.

129. Gilbert AR, Keshavan MS, Diwadkar V, Nutche J, MacMaster F, Easter PC, et al. (2008): Gray Matter Differences between Pediatric Obsessive-Compulsive Disorder Patients and High-Risk Siblings: A Preliminary Voxel-Based Morphometry Study. Neuroscience Letters. 435:45-50.

130. Szeszko P, Christian C, MacMaster F, Lencz T, Mirza Y, Taormina S, et al. (2008): Gray matter structural alterations in psychotropic drug-naive pediatric obsessive-compulsive disorder: an optimized voxel-based morphometry study. American Journal of Psychiatry. 165:1299-1307.

131. Christian CJ, Lencz T, Robinson DG, Burdick KE, Ashtari M, Malhotra AK, et al. (2008): Gray matter structural alterations in obsessive–compulsive disorder: Relationship to neuropsychological functions. Psychiatry Research: Neuroimaging. 164:123-131.

132. Gilbert AR, Mataix-Cols D, Almeida JR, Lawrence N, Nutche J, Diwadkar V, et al. (2008): Brain structure and symptom dimension relationships in obsessive–compulsive disorder: a voxel-based morphometry study. Journal of Affective Disorders. 109:117-126.

133. Kopřivová J, Horáček J, Tintěra J, Praško J, Raszka M, Ibrahim I, et al. (2009): Medial frontal and dorsal cortical morphometric abnormalities are related to obsessive-compulsive disorder. Neuroscience Letters. 464:62-66.

134. van den Heuvel OA, Remijnse PL, Mataix-Cols D, Vrenken H, Groenewegen HJ, Uylings HB, et al. (2009): The major symptom dimensions of obsessive-compulsive disorder are mediated by partially distinct neural systems. Brain. 132:853-868.

135. Matsumoto R, Ito H, Takahashi H, Ando T, Fujimura Y, Nakayama K, et al. (2010): Reduced gray matter volume of dorsal cingulate cortex in patients with obsessive–compulsive disorder: A voxel-based morphometric study. Psychiatry and Clinical Neurosciences. 64:541-547.

136. Britton JC, Rauch SL, Rosso IM, Killgore WDS, Price LM, Ragan J, et al. (2010): Cognitive Inflexibility and Frontal-Cortical Activation in Pediatric Obsessive-Compulsive Disorder. Journal of the American Academy of Child & Adolescent Psychiatry. 49:944-953.

137. Togao O, Yoshiura T, Nakao T, Nabeyama M, Sanematsu H, Nakagawa A, et al. (2010): Regional gray and white matter volume abnormalities in obsessive–compulsive disorder: A voxel-based morphometry study. Psychiatry Research: Neuroimaging. 184:29-37.

138. Lázaro L, Castro-Fornieles J, Cullell C, Andrés S, Falcón C, Calvo R, et al. (2011): A voxel-based morphometric MRI study of stabilized obsessive–compulsive adolescent patients. Progress in Neuro-Psychopharmacology and Biological Psychiatry. 35:1863-1869.

139. Zarei M, Mataix-Cols D, Heyman I, Hough M, Doherty J, Burge L, et al. (2011): Changes in Gray Matter Volume and White Matter Microstructure in Adolescents with Obsessive-Compulsive Disorder. Biological Psychiatry. 70:1083-1090.

140. Exner C, Zetsche U, Martin V, Rief W, Jansen A (2012): Regional gray matter changes in obsessive–compulsive disorder: Relationship to clinical characteristics. Psychiatry Research: Neuroimaging. 202:74-76.

141. Hoexter MQ, Dougherty DD, Shavitt RG, D'Alcante CC, Duran FLS, Lopes AC, et al. (2013): Differential prefrontal gray matter correlates of treatment response to fluoxetine or cognitive-behavioral therapy in obsessive–compulsive disorder. European Neuropsychopharmacology. 23:569-580.

142. Huyser C, van den Heuvel OA, Wolters LH, de Haan E, Boer F, Veltman DJ (2013): Increased orbital frontal gray matter volume after cognitive behavioural therapy in paediatric obsessive compulsive disorder. The World Journal of Biological Psychiatry. 14:319-331.

143. Hou J, Song L, Zhang W, Wu W, Wang J, Zhou D, et al. (2013): Morphologic and Functional Connectivity Alterations of Corticostriatal and Default Mode Network in Treatment-Naïve Patients with Obsessive-Compulsive Disorder. PLoS ONE. 8:e83931.

144. Tan L, Fan Q, You C, Wang J, Dong Z, Wang X, et al. (2013): Structural changes in the gray matter of unmedicated patients with obsessive-compulsive disorder: a voxel-based morphometric study. Neuroscience Bulletin. 29:642-648.

145. Tang W, Li B, Huang X, Jiang X, Li F, Wang L, et al. (2013): Morphometric brain characterization of refractory obsessive–compulsive disorder: Diffeomorphic anatomic registration using exponentiated Lie algebra. Progress in Neuro-Psychopharmacology and Biological Psychiatry. 46:126-131.

146. Spalletta G, Piras F, Fagioli S, Caltagirone C, Piras F (2014): Brain microstructural changes and cognitive correlates in patients with pure obsessive compulsive disorder. Brain and Behavior. 4:261-277.

147. Okada K, Nakao T, Sanematsu H, Murayama K, Honda S, Tomita M, et al. (2015): Biological heterogeneity of obsessive–compulsive disorder: A voxel-based morphometric study based on dimensional assessment. Psychiatry and Clinical Neurosciences. 69:411-421.

148. Kim S-G, Jung WH, Kim SN, Jang JH, Kwon JS (2015): Alterations of Gray and White Matter Networks in Patients with Obsessive-Compulsive Disorder: A Multimodal Fusion Analysis of Structural MRI and DTI Using mCCA+jICA. PLoS ONE. 10:e0127118.

149. Tang W, Huang X, Li B, Jiang X, Li F, Xu J, et al. (2015): Structural brain abnormalities correlate with clinical features in patients with drug-naïve OCD: A DARTEL-enhanced voxel-based morphometry study. Behavioural Brain Research. 294:72-80.

150. Jayarajan RN, Agarwal SM, Viswanath B, Kalmady SV, Venkatasubramanian G, Srinath S, et al. (2015): A Voxel Based Morphometry Study of Brain Gray Matter Volumes in Juvenile Obsessive Compulsive Disorder. Journal of the Canadian Academy of Child and Adolescent Psychiatry. 24:84-91.

151. Shafritz KM, Dichter GS, Baranek GT, Belger A (2008): The Neural Circuitry Mediating Shifts in Behavioral Response and Cognitive Set in Autism. Biological Psychiatry. 63:974-980.

152. Ambrosino S, Bos D, van Raalten T, Kobussen N, van Belle J, Oranje B, et al. (2014): Functional connectivity during cognitive control in children with autism spectrum disorder: an independent component analysis. Journal of Neural Transmission. 121:1145-1155.

153. Yücel M, Harrison BJ, Wood SJ, Fornito A, Wellard RM, Pujol J, et al. (2007): Functional and biochemical alterations of the medial frontal cortex in obsessive-compulsive disorder. Archives of General Psychiatry. 64:946-955.

154. Gu B-M, Park J-Y, Kang D-H, Lee SJ, Yoo SY, Jo HJ, et al. (2008): Neural correlates of cognitive inflexibility during task-switching in obsessive-compulsive disorder. Brain. 131:155-164.

155. Schlösser RG, Wagner G, Schachtzabel C, Peikert G, Koch K, Reichenbach JR, et al. (2010): Fronto - cingulate effective connectivity in obsessive compulsive disorder: A study with fMRI and dynamic causal modeling. Human Brain Mapping. 31:1834-1850.

156. Huyser C, Veltman DJ, Wolters LH, de Haan E, Boer F (2011): Developmental aspects of error and high-conflict-related brain activity in pediatric obsessive–compulsive disorder: a fMRI study with a Flanker task before and after CBT. Journal of Child Psychology and Psychiatry. 52:1251-1260.

157. Pena-Garijo J, Barros-Loscertales A, Ventura-Campos N, Ruipérez-Rodríguez M, Edo-Villamon S, Avila C (2011): Involvement of the thalamic-cortical-striatal circuit in patients with obsessive-compulsive disorder during an inhibitory control task with reward and punishment contingencies. Revista de Neurologia. 53:77-86.

158. Kang D-H, Jang JH, Han JY, Kim J-H, Jung WH, Choi J-S, et al. (2013): Neural correlates of altered response inhibition and dysfunctional connectivity at rest in obsessive–compulsive disorder. Progress in Neuro-Psychopharmacology and Biological Psychiatry. 40:340-346.

159. Marsh R, Horga G, Parashar N, Wang Z, Peterson BS, Simpson HB (2014): Altered activation in fronto-striatal circuits during sequential processing of conflict in unmedicated adults with obsessive-compulsive disorder. Biological Psychiatry. 75:615-622.

Figure 1. Whole-brain meta-analysis of VBM and fMRI differences between ASD, OCD and controls

Fig 1. (A) VBM meta-analysis results for ASD patients relative to controls. **(B)** VBM meta-analysis results for OCD patients relative to controls. **(C)** VBM meta-analysis results for the comparison between ASD patients (vs. controls) and OCD patients (vs. controls). **(D)** VBM meta-analysis results for conjunction/disjunction analysis of ASD and OCD abnormalities (vs. controls). **(E)** fMRI meta-analysis results for ASD patients relative to controls. **(F)** fMRI meta-analysis results for OCD patients relative to controls. **(G)** fMRI meta-analysis results for the comparison between ASD (vs. controls) and OCD (vs. controls). **(H)** fMRI meta-analysis results for conjunction/disjunction analysis of ASD and OCD abnormalities (vs. controls). **(I)** fMRI-VBM multimodal conjunction/disjunction analysis showing overlapping abnormalities in ASD relative to controls. **(J)** fMRI-VBM multimodal conjunction/disjunction analysis showing overlapping abnormalities in OCD relative to controls. **(K)** fMRI-VBM multimodal conjunction/disjunction analysis for the comparison between ASD (vs. controls) and OCD (vs. controls).

Colors: **Cool colors** (blue in ASD, green in OCD) indicate increased brain structure or function in patients versus controls. **Warm colors** (yellow in ASD, red in OCD) indicate decreased brain structure or function in patients versus controls. For Figs. **D** and **H**, orange and light blue indicate disorder-shared decreases/increases in structure/function, respectively. For Fig. **K**, **pink** indicates regions that

were disjunctive across modalities (i.e. increased in one but decreased in the other) in ASD compared to OCD (vs. controls).

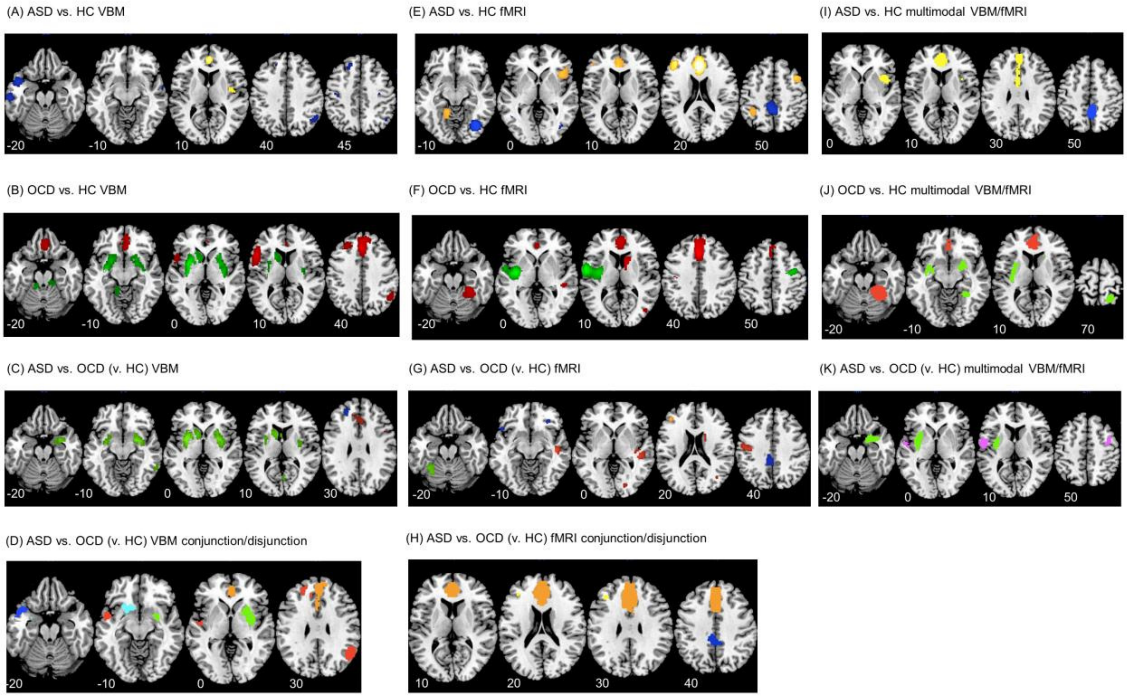

Tables and figure legends

Table 1. Demographic and clinical characteristics of included studies

(A) Demographic and clinical characteristics of the 32 ASD VBM datasets

		Patients			Controls			Brain regions of GMV differences	
Source	**Adult/ child**	**N (% male)**	**Mean age, y**	**Age range**	**N (% male)**	**Mean age, y**	**Age range**	**Patients>HC**	**HC>Patients**
Abell 1999 (93)	adult	15 (80)	28.8	--	15 (80)	25.3	--	L amygdala, R & L cerebellum, vermis, L middle temporal gyrus, R inf. temporal gyrus	R paracingulate gyrus, L IFG, L occipito-temporal junction
McAlonan 2002 (94)	adult	21 (90)	32	18-49	24 (92)	33	18-49	-	R cerebellum, R & L lenticular nucleus, R cingulate gyrus, R precuneus, R & L medial frontal gyrus, R sup. frontal gyrus
Boddaert 2004 (95)	child	21 (76)	9.3	7-15	12 (58)	10.8	7-15	-	R & L sup. temporal sulcus
Waiter 2004 (96)	child	16 (100)	15.4	12-20	16 (100)	15.5	12-20	L sup. frontal gyrus, R fusiform gyrus, R medial frontal gyrus, L middle temporal gyrus, R PCC, R & L sup. temporal gyrus, L lingual gyrus, L IFG, L middle frontal gyrus, L inf. occipital gyrus, L parahippocampal gyrus	R thalamus
Kwon 2004 (97)	child	20 (100)	13.5	10-18	13 (100)	13.6	10-18	-	R inf. temporal gyrus/entorhinal cortex
Rojas 2006 (74)	adult	24 (100)	20.79	7-44	23 (100)	21.4	7-44	-	-
Schmitz 2006 (27)	adult	10 (100)	38	18-52	12 (100)	39	18-52	L IFG, ACC, R sup. frontal gyrus, R & L middle frontal gyrus	-

Brieber 2007 (98)	child	15 (100)	14.2	10-16	15 (100)	13.3	10-16	R supramarginal gyrus, L postcentral gyrus	R & L inf. temporal gyrus/hippocampus-amygdala complex, L middle occipital gyrus, L premotor, L hippocampus
Craig 2007 (99)	adult	14 (0)	37.9	--	19 (0)	35	--	-	L cuneus, L sup./inf. temporal gyrus, R middle temporal gyrus, R ACC
Bonilha 2008 (100)	child	12 (100)	12.4	8-15	16 (100)	13.2	--	R & L IFG, cuneus, cingulate, claustrum, precuneus, thalamus, sup./medial frontal, sup. parietal, sup./inf./middle temporal gyrus, insula, putamen, ACC, fusiform, middle/inf. occipital, lingual gyrus, precentral gyrus, parahippocampal gyrus, cerebellum, R caudate	-
Freitag 2008 (101)	child	15 (87)	17.5	--	15 (87)	18.6	--	-	R intraparietal sulcus
Ke 2008 (102)	child	17 (82)	8.9	6-14	15 (80)	9.73	6-14	R & L supramarginal gyrus, R postcentral, R medial frontal gyrus, R cerebellum	R parahippocampal gyrus
McAlonan 2008 (103)	child	33 (82)	11.6	7-16	55 (86)	10.7	7-16	-	Cerebellum, L striatum/globus pallidus, R caudate, R putamen/globus pallidus, L sup. temporal gyrus, L prefrontal/insula, R mPFC, L pre/postcentral, R precuneus
Langen 2009 (104)	child	99 (92)	12.89	7-24	89 (92)	12.4	6-24	-	-
Wilson 2009 (105)	adult	10 (80)	30.1	22-47	10 (70)	29.4	21-43	-	-
Toal 2010 (106)	adult	65 (88)	31	16-59	33 (91)	32	19-58	-	R & L cerebellum/parahippocampal gyrus/fusiform, R inf. temporal gyrus
Hyde 2010 (107)	adult	15 (100)	22.7	14-33	13 (100)	19.2	14-34	Brainstem, R medial frontal gyrus, L medial OFG, R & L middle frontal gyrus	R postcentral, R & L precentralgyrus

Kosaka 2010 (108)	adult	32 (100)	23.8	17-32	40 (100)	22.5	18-34	-	R insula, R IFG, R inf. parietal
Mengotti 2011 (109)	child	20 (90)	7	4-14	22 (91)	7.7	4-11	R inf. parietal, R sup. occipital, R & L inf. temporal gyrus, L sup. parietal lobule, L precuneus	R IFG, L SMA
Riva 2011 (110)	child	21 (62)	6.5	3-10	21 (62)	6.8	3-10	-	Nucleus accumbens, SMA, R & L insula/putamen, R & L cerebellum, L DLPFC, L inf./sup./middle temporal gyrus, L precuneus, L IFG, L occipito-basal cortex, R postcentral/IPL
Groen 2011 (111)	child	17 (82)	14.4	12-18	25 (88)	15.5	12-18	-	-
Kurth 2011 (112)	child	52 (73)	11.2	5-20	52 (73)	11.1	6-19	-	Hypothalamus
Poustka 2012 (113)	child	18 (89)	9.7	6-12	18 (89)	9.7	6-12	-	-
Calderoni 2012 (114)	child	38 (0)	4.4	2-8	38 (0)	4.4	2-8	L sup. frontal gyrus	-
Ecker 2012 (115)	adult	89 (100)	27	18-43	89 (100)	28	18-43	R & L inf./sup./middle temporal gyrus, R & L fusiform, R & L parahippocampal, R & L insula, L IFG, L putamen, L caudate, L thalamus, R & L middle frontal gyrus, R & L pre/postcentral, R IPL	R inf./middle temporal gyurs, R cerebellum, R fusiform, R lingual gyrus, R & L inf. occipital, R cuneus/precuneus, R PCC, R sup. occipital
Greimel 2013 (116)	adult	51 (100)	18.3	10-50	47 (100)	21.4	8-47	-	ACC, R & L posterior STS, R middle temporal gyrus
Mueller 2013 (117)	adult	12 (75)	35.5	--	12 (67)	33.3	--	-	R & L sup. parietal/supramarginal gyrus, R & L medial temporal gyrus, R & L IFG/OFC, L middle frontal gyrus, L frontal pole, R & L mPFC, L insula
Poulin-Lord 2014 (118)	adult	23 (87)	19.8	14-30	22 (86)	22.6	15-35	-	-
Lim 2015	child	19 (100)	14.9	11-17	33 (100)	14.9	11-17	L middle/sup. temporal gyrus, L medial	-

(119)								frontal gyrus	
Gori 2015 (120)	child	21 (100)	4.17	34-70	20 (100)	4	24-70	-	-
Itahashi 2015 (121)	adult	46 (100)	30.2	19-50	46 (100)	30.5	19-47	-	-
Foster 2015 (122)	child	38 (100)	12.4	6-17	46 (100)	12.6	7-17	R central sulcus, L medial frontal gyrus, R & L IFG, R & L precentral, L middle frontal gyrus, L pre-SMA, R sup. frontal sulcus & gyrus, L ACC, L OFC, L inf. & sup. temporal gyrus, R & L middle temporal gyrus, L Heschel's gyrus, R lingual gyrus, L fusiform gyrus, L postcentral, L PCC, L precuneus, R supramarginal/angular gyrus, L inf. occipital, R & L cuneus, L putamen, L caudate	R sup. temporal gyrus, R & L supramarginal gyrus, L cerebellum

(B) ***Demographic and clinical characteristics of the 30 OCD VBM datasets***

		Patients				Controls			Brain regions of GMV differences	
Source	**Adult/ child**	**N (% male)**	**Mean age,y**	**Age range**	**SSRI use**	**N (% male)**	**Mean age, y**	**Age range**	**Patients>HC**	**HC>Patients**
Pujol 2004 (123)	adult	72 (56)	29.8	18-60	54 med., 13 prev. med., 2 naïve	72 (56)	30.1	8-57	R ventral putamen, L anterior cerebellum, L ventral putamen	R medial frontal gyrus, L gyrus rectus, L posterior insula
Riffkin 2005 (124)	adult	18 (44)	36.1	28-65	3 med., 15 unmed.	18 (44)	34.6	19-54	-	-
Valente 2005 (125)	adult	19 (53)	32.7	--	16 med., 3 naïve	15 (47)	32.3	--	L posterior OFC/AI, L & R parahippocampal/fusiform gyri	L ACC/medial frontal gyri, R angular/supramarginal gyri
Carmona 2007 (126)	child	18 (72)	12.9	--	10 med., 8 naïve	18 (72)	13	--	-	R & L frontal mid, R & L frontal inf. tri., R frontal inf. oper., R frontal sp., L rolandic operculum,

										R & L cingulate, R & L precuneus
Soriano-Mas 2007 (127)	adult	30 (70)	31.9	18-63	26 med., 2 prev. med., 2 naïve	30 (100)	31.8	18-63	-	-
Yoo 2007 (128)	adult	71 (66)	26.6	--	71 med.	71 (66)	26.7	--	R & L postcentral gyrus, R thalamus, L putamen	R cingulate gyrus, R & L IFG, R medial frontal gyrus, R & L insula, L sup. temporal gyrus, R supramarginal gyrus, R precentral gyrus, L middle frontal gyrus
Gilbert 2008a (129)	child	10 (60)	12.9	8-16	0 med., 10 naïve	10 (60)	13.4	9-17	-	L anterior cingulate, R & L medial sup. frontal gyrus
Szeszko 2008 (130)	child	37 (38)	13	--	0 med., 37 naïve	26 (35)	13	--	R & L putamen, R & L OFC, R sup. temporal, R frontal pole, R & L parietal	R & L occipital
Christian 2008 (131)	adult	21 (71)	38	--	17 med., 4 unmed.	21 (71)	38.9	--	L thalamus	-
Gilbert 2008b (132)	adult	25 (52)	37.5	27-62	20 med., 5 unmed.	20 (45)	29.8	19-51	R & L midbrain	R & L BA 9, 6, 46, R BA 8
Koprivova 2009 (133)	adult	14 (36)	28.6	--	10 med., 13 prev. med.m 1 naïve	15 (40)	28.7	--	-	R lingual gyrus, R & L medial/sup. frontal gyrus, ACC, R sup. occipital gyrus, R inf. parietal lobule, R sup. temporal gyrus, L middle temporal gyrus, R precentral gyrus, pons/mesencephalon, R fusiform gyrus, L cerebellum
van den Heuvel 2009 (134)	adult	55 (29)	33.7	19-54	0 med., 30 prev. med., 25 naïve	50 (40)	31.4	21-53	-	L lateral OFC, L DLPFC, L IFC, R & L mPFC

Matsumoto 2010 (135)	adult	16 (44)	32.8	--	6 med., 6 prev med., 4 naïve	31 (44)	32.6	--	-	R dorsal PCC, L caudal PCC
Britton 2010 (136)	child	15 (60)	13.5	10-17	15 med., 0 naïve	20 (65)	13.6	10-17	Medial frontal gyrus, OFC, R ACC, IFG	-
Togao 2010 (137)	adult	23 (46)	32.6	21-56	18 med., 5 naïve	26 (46)	34.6	21-48	-	R & L medial PFC, R OFC, R DLPFC, R middle temporal gyrus/middle occipital gyrus, L middle occipital gyrus
Lazaro 2011 (138)	child	27 (56)	15.6	--	27 med., 0 naïve	27 (48)	16.1	--	-	-
Zarei 2011 (139)	child	26 (54)	16.6	12-18	16 med., 10 naïve	26 (54)	16.5	12-18	R & L caudate nuclei, R posterior putamen, R globus pallidus	-
Exner 2012 (140)	adult	23 (39)	31.3	--	13 med., 10 unmed.	36 (39)	30.4	--	L temporoparietal/superior temporal lobe	dorsal mediofrontal cortex
Hoexter 2013 (141)	adult	38 (40)	31.5	--	0 med., 38 naïve	36 (36)	27.8	--	PCC, R IFG, L postcentral gyrus/cortex	L & R DLPFC, L mid/sup. occipital, R IPL, R inf. temporal
Huyser 2013 (142)	child	29 (38)	13.8	9-18	0 med., 2 prev. med., 27 naïve	29 (38)	13.6	9-18	L insula/frontal pole, L sup. parietal, L supramarginal gyrus	-
Hou 2013 (143)	adult	33 (55)	25.3	--	0 med., 33 naïve	33 (55)	25	--	L caudate, L thalamus, PCC	R & L medial OFC, L ACC, L IFG
Tan 2013 (144)	adult	28 (68)	25.4	--	0 med., 18 prev. med., 10 naïve	22 (68)	27.9	--	R & L middle temporal gyri, R & L middle occipital gyri, R & L globus pallidus, R inf. parietal gyrus, L sup. parietal gyrus, R parahippocampus, R supramarginal gyrus, R medial sup. frontal gyrus, L inf. frontal opercular gyrus	-
Subira 2013 (58)	adult	95 (56)	33.4	--	95 med., 0 naïve	95 (58)	33.9	--	R & L putamen	L anterior temporal lobe

Tang 2013 (145)	adult	18 (61)	25.5	--	0 med., 18 prev. med.	26 (58)	25.2	--	L putamen	L PCC, L mediodorsal thalamus
Hashimoto 2014 (57)	adult	39 (46)	34.1	--	39 med., 0 naïve	30 (47)	32.5	--	-	R thalamus, R caudate, L PCC, L DLPFC
Spalletta 2014 (146)	adult	20 (60)	33.1	--	11 med., 7 prev. med., 2 naïve	20 (60)	35.2	--	-	-
Okada 2015 (147)	adult	37 (38)	34.4	22-58	32 med., 3 prev. med., 2 naïve	37 (38)	36.8	22-60	L precentral gyrus	R middle temporal gyrus, L DLPFC, R PCC, R OFC, R supramarginal gyrus, L IFG
Kim 2015 (148)	adult	30 (67)	25	--	0 med., 8 prev. med., 22 naïve	34 (68)	23.9	--	-	-
Tang 2015 (149)	adult	26 (58)	25.5	--	0 med., 26 naïve	32 (53)	26.2	--	L insula, R parahippocampal gyrus	R DLPFC, L sup. temporal gyrus, L precuneus, R precentral
Jayarajan 2015 (150)	child	15 (53)	14.1	--	13 med., 2 naïve	15 (53)	14.3	--	-	-

(C) ***Demographic and clinical characteristics of the 12 ASD fMRI datasets***

			Patients			Controls			Brain regions of activation differences	
Source	**Adult/ child**	**Task**	**N (% male)**	**Mean age, y**	**Age range**	**N (% male)**	**Mean age, y**	**Age range**	**Patients>HC**	**HC>Patients**
Schmitz 2006 (27)	adult	GNG Switch Stroop	10 (100)	38	18-52	12 (100)	39	18-52	GNG: L mid/IFG, L OFC; Stroop: L insula; Switch: R IPL, L mesial parietal	-
Kennedy 2006 (81)	adult	Stroop	15 (100)	25.5	16-44	14 (100)	26.1	--	R supramarginal gyrus, R precuneus, R & L IPL, R sup. frontal gyrus, L ACC	-
Kana 2007	adult	GNG	12 (92)	26.8	--	12 (92)	22.5	--	-	L inf. temporal gyrus, R

(26)										parahippocampal gyrus, R calcarine sulcus, R premotor, R middle cingulate, R & L postcentral, R insula/IFG, L lingual gyrus
Shafritz 2008 (151)	adult	Switch	18 (89)	22.3	--	15 (87)	24.3	--	-	DLPFC, ACC, inf. parietal sulcus, L insula
Vaidya 2011 (24)	child	Stroop	15 (100)	10.8	7-12	18 (100)	11.0	--	-	ACC, L middle frontal gyrus, R caudate
Fan 2012 (25)	adult	Flanker	12 (75)	30	--	12 (83)	28	--	-	ACC
Duerden 2013 (21)	adult	GNG	13 (69)	25.9	19-39	17 (71)	29	20-43	R IFG, R fusiform gyrus	R middle frontal gyrus
Solomon 2014 (28)	child	POP	27 (19)	15.4	12-18	27 (19)	16.1	12-18	-	L PCC, L lingual gyrus, L middle occipital
Chantiluke 2014 (19)	child	Stop	19 (100)	14.7	10-17	25 (100)	13.4	10-17	R & L IFG	L IPL
Ambrosino 2014 (152)	child	GNG	19 (100)	11.5	9-12	19 (100)	11.1	9-14	-	-
Daly 2014 (22)	adult	GNG	14 (100)	31	--	14 (100)	31	--	R caudate, R cerebellum	R IFC, L thalamus
Shafritz 2015 (23)	adult	GNG	15 (80)	18.1	13-23	15 (80)	18.4	12-23	-	R VLPFC/insula

(D) ***Demographic and clinical characteristics of the 14 OCD fMRI datasets***

			Patients				Controls			Brain regions of activation differences	
Source	**Adult/ child**	**Task**	**N (% male)**	**Mean age, y**	**Age range**	**SSRI use**	**N (% male)**	**Mean age, y**	**Age range**	**Patients>HC**	**HC>Patients**
Nakao 2005 (84)	adult	Stroop	24 (38)	33.9	21-54	0 med., 24 unmed.	14 (36)	30.2	24-43	R frontal cortex	ACC, R caudate, R & L temporal cortex, R brainstem
Roth 2007	adult	GNG	12 (43)	37.8	--	6 med., 6	14 (42)	34.9	--	R & L postcentral, R cuneus, L	R IFG, R medial/sup. frontal

(85)						unmed.				supramarginal gyrus	gyrus, R fusiform, R middle temporal gyrus, R thalamus
Yucel 2007 (153)	adult	MSIT	19 (53)	33.7	--	11 med., 8 unmed.	19 (53)	30.6	--	SMA, L sup. parietal, L precentral, R middle frontal gyrus, L IFG, L putamen	Rostral ACC, L IFG, R fusiform gyrus
Gu 2008 (154)	adult	Switch	21 (86)	23.6	--	11 med., 2 prev. med., 8 naïve	21 (86)	24.8	--	-	R DLPFC, R & L premotor, L VLPFC, R OFC, R & L medial frontal cortex, ACC, R & L PCC, R uncus, R insula, R & L parietal, R middle/sup. temporal gyrus, R & L occipital, R & L caudate
Woolley 2008 (55)	child	Stop Stroop Switch	10 (100)	14.3	12-16	8 med., 2 unmed.	9 (100)	14.5	12-16	-	Stop: R & L OFC, R thalamus/BG; Stroop: R & L cerebellum, R mid. temporal gyrus; Switch: R & L IPL/sup. temp, R & L cerebellum
Page 2009 (56)	adult	GNG Stroop Switch	10 (100)	39.1	--	0 med., 4 prev. med., 6 naïve	11 (100)	34.1	--	GNG: R & L PCC/middle temporal gyrus, L cerebellum, R vmPFC, R middle/sup. temporal gyrus, R premotor; Stroop: L cerebellum/PCC; Switch: -	GNG: L cerebellum, R & L vmOFC/ACC, R BG/thalamus/hippocampus; Stroop: R mid/sup. temp. gyrus, L IPL/sup. temp, L sup. parietal/precuneus; Switch: L DLPFC/ACC, L precuneus/PCC
Fitzgerald 2010 (91)	child	MSIT	18 (33)	13.9	8-18	12 med., 6 naïve	18 (33)	14.1	8-18	-	-
Britton 2010 (136)	child	Set-shift	15 (60)	13.5	10-17	15 med.	20 (65)	13.6	10-17	-	-
Schlosser 2010 (155)	adult	Stroop	21 (24)	31.3	--	2 med., 10 unmed., 9 naïve	21 (24)	28.8	--	R & L DLPFC	L occipital lobe
Huyser 2011 (156)	child	Flanker	25 (36)	14.0	9-19	0 med., 1 prev.	25 (36)	13.7	8-19	-	-

						med., 24 naïve					
Pena-Garijo 2011 (157)	adult	GNG	13 (39)	37.1	--	8 med., 5 unmed.	13 (46)	37.1	--	R occipital, L IPL, L cerebellum	L ACC, R caudate, dmPFC
Kang 2013 (158)	adult	Stop	18 (66)	24.9	--	0 med., 6 prev. med., 12 naïve	18 (66)	24.7	--	R & L sup. parietal, L cerebellum, R parahippocampal cortex	L precentral, R fusiform, L middle temporal, R middle occipital, R sup. temporal, L angular cortex, R putamen, R & L caudate, R ACC, R calcarine, R middle cingulate, L cerebellum
Marsh 2014 (159)	adult	Stroop	22 (50)	30	--	0 med., 8 prev. med., 14 naïve	22 (50)	30.1	--	-	ACC, R & L sup. frontal gyrus, R & L middle frontal gyrus
Morein-Zamir 2015 (54)	adult	Switch GNG	19 (74)	37.8	--	14 med., 5 unmed.	19 (74)	36.2	--	Switch: - ; GNG: L cuneus, R precentral gyrus, L caudate	Switch: L & R fusiform, R middle temporal, L & R middle occipital, L lingual, L SMA & pre-SMA, R thalamus, L middle frontal, R precuneus; GNG: -

Abbreviations: %, percentage, ACC, anterior cingulate cortex; ASD, autism spectrum disorders; DLPFC, dorsolateral prefrontal cortex; dmPFC, dorsomedial prefrontal cortex; fmri, functional magnetic resonance imaging; GNG, go/no-go; IFG, inferior frontal gyrus; inf., inferior; L, left; med., medicated; MSIT, multisource interference task; mid, middle; OCD, obsessive compulsive disorder; PCC, posterior cingulate cortex; POP, preparing to overcome prepotency; prev. R, right; SMA, supplementary motor area; SSRI, selective serotonin reuptake inhibitor; STS, superior temporal sulcus; sup., superior; temp., temporal; unmed. unmedicated (at time of scan); VLPFC, ventrolateral prefrontal cortex; vmOFC, ventromedial orbitofrontal cortex; VBM, voxel-based morphometry; y, years

Table 2. Demographic information of meta-analysis samples

(A) Total study sample				
	ASD patients	**OCD patients**	**ASD controls**	**OCD controls**
VBM				
n	911	928	932	942
% males	85	53	84	51
Mean age[a], y (SD)	18.5 (9.1)	27.8 (7.6)	18.1 (9.0)	27.6 (7.3)
Age range	2-70	8-65	2-70	8-63
fMRI				
n	188	247	196	244
% males	88	54	89	55
Mean age[a], y (SD)	21.4 (7.7)	27.1 (8.9)	21.3 (8.3)	25.7 (11.0)
Age range	7-52	8-54	9-52	8-43
Mean IQ[a] (SD)	109.0 (5.5)	108.0 (5.2)	114.9 (5.0)	113.5 (3.6)
(B) Age and sex-matched sub-sample				
	ASD patients	**OCD patients**	**ASD controls**	**OCD controls**
VBM				
n	258	412	295	441
% males	74	58	73	55
Mean age[a], y (SD)	18.0 (11.9)	25 (7.7)	18.6 (11.3)	24.8 (7.2)
Age range	2-52	10-63	2-52	10-63
fMRI				
n	140	127	140	134
% males	84	70	86	70
Mean age[a], y (SD)	22.4 (6.9)	27.0 (9.8)	22.5 (6.8)	25.9 (8.2)
Age range	7-44	10-17	12-43	10-17
Mean IQ[a] (SD)	108.4 (6.7)	109.9 (4.9)	116.2 (4.2)	113.8 (3.6)

[a]weighted averages
NB: age ranges were not available for all studies, above values based on available information; see supplementary material (Tables S1-S4) for further details
Abbreviations: ASD, autism spectrum disorders; fMRI, functional magnetic resonance imaging; OCD, obsessive compulsive disorder; SD, standard deviation; VBM, voxel-based morphometry; y, years.

Table 3. Meta-analysis results for VBM studies in ASD and OCD

Contrast	Brodmann areas	MNI x,y,z coordinates	SDM *z*-score	*P* value	No. of voxels
(A) ASD versus HC					
ASD < HC					
r/d ACC/MPFC	32/24/9/10	4,44,16	-1.644	.001	345
R posterior insula	-	44,-12,12	-1.473	.002	65
L cerebellum VIII	-	-10,-66,-48	-1.453	.003	52
ASD > HC					
L middle/sup. temporal lobe	38/21	-44,6,-26	2.436	<.0001	1047
R IPL/occipital lobe	39/19	50,-58,36	1.576	<.001	209
L middle frontal gyrus	8	-20,30,46	1.667	<.001	78
L precentral gyrus	6/4	-38,-14,50	1.482	.002	52
R inf. temporal gyrus	20	60,-4,-14	1.486	.002	49
R precentral gyrus	6/4	34,-16,46	1.353	.003	10
(B) OCD versus HC					
OCD < HC					
v/r/d ACC/MPFC	25/11/24/32/9	-2,30,34	-2.737	<.0001	3199
L VLPFC/premotor cortex/insula/STL	44/45/6/42	-52,18,12	-2.442	<.0001	1095
R IPL	7	52,-56,38	-1.817	<.001	355
L MFG/DLPFC	9	-28,34,38	-1.862	<.001	182
L VLPFC	47	-44,44,-4	-1.466	.004	16
OCD > HC					
L putamen/caudate/NAcc/ pallidum/amygdala/insula	-	-28,4,-2	2.360	<.0001	1582
R putamen/NAcc/ pallidum/amygdala/insula	-	24,4,-2	2.010	<.0001	834
L cerebellum IV/V	-	-14,-40,-20	1.444	<.001	371
R cerebellum IV/V	-	12,-30,-22	1.276	.001	92
L postcentral gyrus	3/1/2	-26,-36,62	1.071	.004	31
R superior parietal gyrus	7	16,-56,72	1.146	.003	23
R cerebellum	-	22,-38,-16	1.053	.004	17
(C) ASD (vs. HC) versus OCD (vs. HC)					
ASD (vs. HC) < OCD (vs. HC)					
R putamen/caudate/NAcc/ pallidum/amygdala/insula/STL	21/38	26,4,-4	-2.307	<.0001	1288
L putamen/caudate/NAcc/ pallidum/amygdala/insula	-	-28,4,-2	-2.375	<.0001	774
L caudate	-	-8,12,2	-2.020	<.001	442
(R inferior temporal lobe)*	37	62,-48,-12	-1.482	.001	95
(R cuneus)*	31	4,-70,10	-1.438	.002	51
ASD (vs. HC) > OCD (vs. HC)					
dACC/MPFC	32/9	-12,40,24	1.390	<.001	304
L superior frontal gyrus	9/8	-22,42,26	1.758	<.0001	121
(R MFG/premotor)*	9/6	40,4,42	1.009	.002	60

Bold indicates regions which survive age and sex-matched subgroup analysis
()* indicates regions which did not survive age and sex-matched subgroup analysis

Abbreviations: ACC, anterior cingulate cortex; ASD, Autism spectrum disorders; BG, basal ganglia; d, dorsal; DLPFC, dorsolateral prefrontal cortex; HC, healthy controls; inf., inferior; IPL, inferior parietal lobe; L, left; MPFC, medial prefrontal cortex; MFG, middle frontal gyrus; MNI, Montreal Neurological Institute; NAcc, nucleus accumbens; OCD, obsessive compulsive disorder; R, right; r, rostral; STL, superior temporal lobe; v, ventral; vmOFC, ventromedial orbitofrontal cortex; VLPFC, ventrolateral prefrontal cortex; VBM, voxel-based morphometry.

Table 4. Meta-analysis results for fMRI studies of inhibitory control in ASD and OCD

Contrast	Brodmann areas	MNI x,y,z coordinates	SDM *z*-score	*P* value	No. of voxels
(A) ASD versus HC					
ASD < HC					
r/d ACC/MPFC	32/24/9	0,32,22	-1.862	<.0001	2116
L DLPFC	46/9	-44,34,26	-1.821	<.0001	589
R VLPFC/anterior insula	47	44,20,0	-1.466	.001	282
L cerebellum (vermis)	-	-12,-46,-10	-1.418	.001	282
L IPL	40/7	-32,-52,54	-1.378	.002	206
R MFG/premotor cortex	6/8	40,14,50	-1.532	<.001	181
ASD > HC					
Precuneus/PCC	7/5/31/23	-4,-40,54	1.370	<.001	1017
R inf. temporal/occipital lobe	37/19	36,-68,-12	1.534	<.0001	526
L middle temporal gyrus	--	-46,-54,6	1.069	<.001	45
(B) OCD versus HC					
OCD < HC					
v/r/d ACC/MPFC	11/10/9/32/24	-2,26,42	-2.900	<.0001	3717
R caudate	-	14,8,14	-2.408	<.0001	500
R cerebellum	-	30,-46,-16	-2.133	<.001	311
R STL/middle temporal gyrus	21/22	44,-20,-10	-1.893	.001	136
L postcentral gyrus	3/1/2	-40,-16,38	-1.805	.002	30
R PCC	23	16,-38,38	-1.888	.001	17
OCD > HC					
L insula/putamen/premotor cortex/VLPFC/STL	6/44/22	-56,-4,6	1.651	<.0001	1890
R premotor cortex	4/6	36,-8,54	1.257	<.001	321
L superior parietal cortex	7	-18,-62,70	1.034	.001	17
(C) ASD (vs. HC) versus OCD (vs. HC)					
ASD (vs. HC) < OCD (vs. HC)					
L MFG/DLPFC	9/46	-40,34,28	-1.316	<.001	339
(L cerebellum IV)*	-	-30,-50,-22	-1.005	.001	553
ASD (vs. HC) > OCD (vs. HC)					
R STL/middle temporal lobe	21	44,-22,-8	2.394	<.0001	371
L pre/postcentral gyrus/IPL	6/4/3/1/2	-40,-16,40	1.940	<.001	310
R PCC	23	16,-42,36	1.742	.001	22
(PCC/precuneus)*	23/31/7	-4,-42,46	1.719	.001	240
(R VLPFC)*	11/47	30,34,-12	1.761	.001	76
(R occipital lobe/cuneus)*	19/30	20,-82,4	1.753	.001	52
(L VLPFC)*	47/38	-48,22,-8	1.574	.003	42
(R caudate)*	-	18,4,22	1.693	.001	25
(R occipital)*	19	38,-68,20	1.599	.002	22

Bold indicates regions which survived age and sex-matched subgroup analysis
()* indicates regions which did not survive age and sex-matched subgroup analysis
Abbreviations: ACC, anterior cingulate cortex; ASD, Autism spectrum disorders; d, dorsal; DLPFC, dorsolateral prefrontal cortex; HC, healthy controls; inf., inferior; IPL, inferior parietal lobe; L, left; MPFC, medial prefrontal cortex; MFG, middle frontal gyrus; MNI, Montreal Neurological Institute; OCD, obsessive compulsive disorder; PCC: posterior cingulate cortex; R, right; r, rostral; STL, superior temporal lobe; v, ventral; vmOFC, ventromedial orbitofrontal cortex; VLPFC, ventrolateral prefrontal cortex; VBM, voxel-based morphometry.