



## King's Research Portal

DOI:  
[10.1093/qjmed/hcx046](https://doi.org/10.1093/qjmed/hcx046)

*Document Version*  
Publisher's PDF, also known as Version of record

[Link to publication record in King's Research Portal](#)

*Citation for published version (APA):*  
Joseph, J. P., & Redwood, S. R. (2017). Mobile digital health devices and the diagnosis in real-time of myocardial ischaemia. *QJM*, 110(5), 309-310. Article hcx046. <https://doi.org/10.1093/qjmed/hcx046>

### **Citing this paper**

Please note that where the full-text provided on King's Research Portal is the Author Accepted Manuscript or Post-Print version this may differ from the final Published version. If citing, it is advised that you check and use the publisher's definitive version for pagination, volume/issue, and date of publication details. And where the final published version is provided on the Research Portal, if citing you are again advised to check the publisher's website for any subsequent corrections.

### **General rights**

Copyright and moral rights for the publications made accessible in the Research Portal are retained by the authors and/or other copyright owners and it is a condition of accessing publications that users recognize and abide by the legal requirements associated with these rights.

- Users may download and print one copy of any publication from the Research Portal for the purpose of private study or research.
- You may not further distribute the material or use it for any profit-making activity or commercial gain
- You may freely distribute the URL identifying the publication in the Research Portal

### **Take down policy**

If you believe that this document breaches copyright please contact [librarypure@kcl.ac.uk](mailto:librarypure@kcl.ac.uk) providing details, and we will remove access to the work immediately and investigate your claim.

## CASE REPORT

# Mobile digital health devices and the diagnosis in real-time of myocardial ischaemia

J.P. Joseph\* and S.R. Redwood

From the King's College London British Heart Foundation Centre of Excellence, The Rayne Institute, St. Thomas' Hospital Campus, London, UK

\*Address correspondence to Jubin P. Joseph, Cardiovascular Department, Kings College London, St Thomas' Hospital, London SE1 7EH, UK.  
email: jubin.joseph@kcl.ac.uk

## Learning points for clinicians

- Mobile digital health devices that provide remote, patient-generated information are commercially available. This can challenge traditional health care delivery models, but can potentially reduce healthcare expenditure and improve clinical outcomes. Previous, difficult to establish diagnoses, such as coronary artery spasm, may be made with greater certainty using these devices.

A 61-year-old man presented with sub-sternal chest pain at rest associated with sweating. He had a family history for premature cardiovascular disease, but otherwise no cardiac risk factors and an excellent exercise tolerance. The symptoms had been recurrent for 3 months, and on one occasion he presented to the emergency department where both 12-lead electrocardiogram (ECG) and troponin were normal. He was prescribed GTN spray, and following cardiology review went to have a normal exercise stress echocardiogram.

He continued to experience episodes of chest discomfort which resolved with GTN administration, during one of these episodes he acquired a tracing using a handheld ECG device (AliveCor Inc., USA) attached to a smartphone. The single ECG lead tracing demonstrated ST-segment elevation with intermittent ectopy (Figure 1A) which resolved following the administration of GTN (Figure 1B).

Due to the transient ST-segment elevation, he was admitted to hospital and underwent urgent coronary angiography. This demonstrated minor atheromatous changes which, following pressure wire assessment using intravenous adenosine, were demonstrated

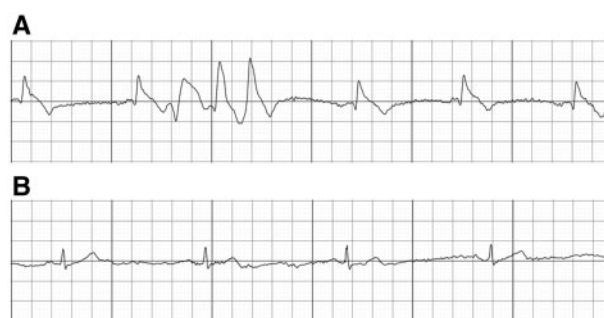


Figure 1. Single-lead ECG recordings obtained with the AliveCor device during a period of chest pain at rest demonstrated ST-elevation and an ectopic triplet (A) and following sublingual GTN administration normalization of the ST segments (B)—both traces obtained with mains filter: 50 Hz; Scale: 25 mm/s, 10 mm/mV.

not to be physiologically significant. Given the absence of exertional symptoms, normal stress echocardiogram and invasive assessment, the decision was made not to proceed to angioplasty.

A diagnosis of coronary artery spasm was made and treatment with vasodilators (diltiazem) and statin initiated. At 6 months clinic follow-up, the patient was asymptomatic with excellent exercise capacity.

## Discussion

Recent technological advances have resulted in a wide range of mobile digital health (mHealth) devices that are disrupting traditional health care delivery. These miniaturized diagnostic instruments are providing remote, patient-generated information that can potentially reduce healthcare expenditure and improve clinical outcomes.<sup>1</sup>

Submitted: 26 January 2017; Revised (in revised form): 13 February 2017

© The Author 2017. Published by Oxford University Press on behalf of the Association of Physicians.

This is an Open Access article distributed under the terms of the Creative Commons Attribution License (<http://creativecommons.org/licenses/by/4.0/>), which permits unrestricted reuse, distribution, and reproduction in any medium, provided the original work is properly cited.

AliveCor incorporates electrodes for wireless cardiac telemetry monitoring, and approved for use by the US Food and Drug Administration (US-FDA) and EU Medical Device Directive (EU-MDD) in 2013. When the user rests their fingers on the sensors, the device detects electrical impulses (representative of Lead I when held between the right and left hand) and converts it to an ultrasound signal that is transmitted to the mobile device's microphone to produce a 30 s rhythm strip. Previous studies have established clinical effectiveness in detecting arrhythmias, but this is the first reported case of mHealth products identifying acute myocardial ischaemia.<sup>2</sup>

In 1959, Prinzmetal *et al.* described 'variant angina' and postulated that the condition was due to vasospasm.<sup>3</sup> The pathophysiology of coronary artery spasm remains unclear, but is thought to involve endothelial dysfunction and hyper-reactivity of coronary artery smooth muscle cells. Classically, this presents with severe chest pain, usually at rest, with a concurrent ECG showing transient ST elevation and prompt resolution with short-acting nitrates—all of which are demonstrated in our reported case.<sup>4</sup>

Contemporary diagnosis of coronary artery spasm relies on provocation testing with intracoronary acetylcholine during invasive coronary angiography—although this remains a controversial area. Many cardiologists have questioned the clinical utility of provocation testing as the results are difficult to interpret and studies have demonstrated high proportions of patients with provoked spasm during invasive testing.<sup>5</sup> The gold standard for diagnosis would be demonstrating transient ST-elevation during episodes of vasospasm in a patient with unobstructed coronary arteries. This has proven elusive due to the unpredictable nature of symptoms and the impracticality of prolonged rhythm monitoring.

This reported case provides a succinct demonstration how emerging mHealth devices can provide new insights into previously difficult to establish diagnoses. These devices are providing patients with accurate diagnostic tools that have the

potential to challenge the way we practice medicine. Future work will focus on how best to analyse these vast quantities of data, identifying clinically useful measures and ways to integrate them into our existing healthcare systems to improve patient outcomes.

## Funding

Dr Jubin Joseph receives Clinical Training Research Fellowship funding from the British Heart Foundation (FS/15/52/31587).

Conflict of interest: None declared.

## References

1. Bhavnani SP, Narula J, Sengupta PP. Mobile technology and the digitization of healthcare. *Eur Heart J* 2016; **37**:1428–38.
2. Tarakji KG, Wazni OM, Callahan T, Kanj M, Hakim AH, Wolski K, *et al.* Using a novel wireless system for monitoring patients after the atrial fibrillation ablation procedure: the iTransmit study. *Heart Rhythm* 2015; **12**:554–9.
3. Prinzmetal M, Kennamer R, Merliss R, Wada T, Bor N. Angina pectoris I. A variant form of angina pectoris. *Am J Med* 1959; **27**:375–88.
4. Nakamura M, Takeshita A, Nose Y. Clinical characteristics associated with myocardial infarction, arrhythmias, and sudden death in patients with vasospastic angina. *Circulation* 1987; **75**:1110–6.
5. Ong P, Athanasiadis A, Borgulya G, Vokshi I, Bastiaenen R, Kubik S, *et al.* Clinical usefulness, angiographic characteristics and safety evaluation of intracoronary acetylcholine provocation testing among 921 consecutive Caucasian patients with unobstructed coronary arteries. *Circulation* 2014; **129**: 1723–30.